

AQUATIC EFFECTS TECHNOLOGY EVALUATION (AETE) PROGRAM

Technical Evaluation of Histopathology as an Environmental Monitoring Tool for the Mining Industry in Canada

AETE Project 2.2.2

Technical Evaluation of Histopathology as an Environmental Monitoring Tool for the Mining Industry in Canada

Literature Review and Comments

June 16, 1997

for

Diane Campbell
Manager of Aquatic Effects
Natural Resources Canada
555 Booth St. 3rd Floor
Ottawa, ON K1A 0G1
CANADA

GLOBALTOX INTERNATIONAL CONSULTANTS INC.

1794 COURTWOOD CRES., OTTAWA, ON K2C 2B5

PHONE: (613) 723-5788

FAX: (613) 723-2594



AQUATIC EFFECTS TECHNOLOGY EVALUATION PROGRAM

Notice to Readers

Technical Evaluation of Histopathology as an Environmental Monitoring Tool for the Mining Industry in Canada

The Aquatic Effects Technology Evaluation (AETE) program was established to review appropriate technologies for assessing the impacts of mine effluents on the aquatic environment. AETE is a cooperative program between the Canadian mining industry, several federal government departments and a number of provincial governments; it is coordinated by the Canada Centre for Mineral and Energy Technology (CANMET). The program was designed to be of direct benefit to the industry, and to government. Through technical and field evaluations, it identified cost-effective technologies to meet environmental monitoring requirements. The program included three main areas: acute and sublethal toxicity testing, biological monitoring in receiving waters, and water and sediment monitoring.

The technical evaluations were conducted to document certain tools selected by AETE members, and to provide the rationale for doing a field evaluation of the tools or provide specific guidance on field application of a method. In some cases, the technical evaluations included a go/no go recommendation that AETE takes into consideration before a field evaluation of a given method is conducted.

The technical evaluations were published although they do not necessarily reflect the views of the participants in the AETE Program. The technical evaluations should be considered as working documents rather than comprehensive literature reviews. **In this respect, certain members of the Task group felt that the technical review of fish histopathology did not adequately consider the available grey literature and the present scientific experience in histopathology.**

The purpose of the technical evaluations focussed on specific monitoring tools. AETE committee members would like to stress that no one single tool can provide all the information required for a full understanding of environmental effects in the aquatic environment.

For more information on the monitoring techniques, the results from their field application and the final recommendations from the program, please consult the AETE Synthesis Report to be published in the spring of 1999.

Any comments concerning the content of this report should be directed to:

Geneviève Béchard
Manager, Metals and the Environment Program
Mining and Mineral Sciences Laboratories - CANMET
Room 330, 555 Booth Street, Ottawa, Ontario, K1A 0G1
Tel.: (613) 992-2489 Fax: (613) 992-5172
E-mail: gbechard@nrcan.gc.ca



PROGRAMME D'ÉVALUATION DES TECHNIQUES DE MESURE D'IMPACTS EN MILIEU AQUATIQUE

Avis aux lecteurs

Évaluation technique des paramètres histopathologiques comme méthode de surveillance de l'environnement pour l'industrie minière du Canada

Le Programme d'évaluation des techniques de mesure d'impacts en milieu aquatique (ÉTIMA) visait à évaluer les différentes méthodes de surveillance des effets des effluents miniers sur les écosystèmes aquatiques. Il est le fruit d'une collaboration entre l'industrie minière du Canada, plusieurs ministères fédéraux et un certain nombre de ministères provinciaux. Sa coordination relève du Centre canadien de la technologie des minéraux et de l'énergie (CANMET). Le programme était conçu pour bénéficier directement aux entreprises minières ainsi qu'aux gouvernements. Par des évaluations techniques et des études de terrain, il a permis d'évaluer et de déterminer, dans une perspective coût-efficacité, les techniques qui permettent de respecter les exigences en matière de surveillance de l'environnement. Le programme comportait les trois grands volets suivants : évaluation de la toxicité aiguë et sublétales, surveillance des effets biologiques des effluents miniers en eaux réceptrices, et surveillance de la qualité de l'eau et des sédiments.

Les évaluations techniques ont été menées dans le but de documenter certains outils de surveillance sélectionnés par les membres de l'ÉTIMA et de fournir une justification pour l'évaluation sur le terrain de ces outils ou de fournir des lignes directrices quant à leur application sur le terrain. Dans certains cas, les évaluations techniques pourraient inclure des recommandations relatives à la pertinence d'effectuer une évaluation de terrain que les membres de l'ÉTIMA prennent en considération.

Les évaluations techniques sont publiées bien qu'elles ne reflètent pas nécessairement toujours l'opinion des membres de l'ÉTIMA. Les évaluations techniques devraient être considérées comme des documents de travail plutôt que des revues de littérature complètes. **À cet égard, certains membres du groupe de travail étaient d'avis que l'étude technique de l'histopathologie des poissons ne prenait pas suffisamment en considération la littérature grise et le savoir-faire scientifique actuel dans le domaine de l'histopathologie.**

Les évaluations techniques visent à documenter des outils particuliers de surveillance. Toutefois, les membres de l'ÉTIMA tiennent à souligner que tout outil devrait être utilisé

conjointement avec d'autres pour permettre d'obtenir l'information requise pour la compréhension intégrale des impacts environnementaux en milieu aquatique.

Pour des renseignements sur l'ensemble des outils de surveillance, les résultats de leur application sur le terrain et les recommandations finales du programme, veuillez consulter le Rapport de synthèse ÉTIMA qui sera publié en février 1999.

Les personnes intéressées à faire des commentaires concernant le contenu de ce rapport sont invitées à communiquer avec M^{me} Geneviève Béchard à l'adresse suivante :

Geneviève Béchard
Gestionnaire, Programme des métaux et de l'environnement
Laboratoires des mines et des sciences minérales - CANMET
Pièce 330, 555, rue Booth, Ottawa (Ontario), K1A 0G1
Tél.: (613) 992-2489 / Fax : (613) 992-5172
Courriel : gbechard@nrcan.gc.ca

TABLE OF CONTENTS

DISCLAIMER	i
I. EXECUTIVE SUMMARY	ii
A. SUMMARY	ii
B. RÉSUMÉ.....	iv
II. SCOPE OF THIS REVIEW	1
A. TERMS OF REFERENCE.....	1
1. <i>Background:</i>	1
2. <i>Objectives:</i>	2
3. <i>Task 1: Literature Review</i>	2
4. <i>Task 2: Assess Possible Uses and Benefits of Histopathology</i>	2
5. <i>Task 3: Critical Evaluation of Histopathology as a Monitoring Tool</i>	4
III. INTRODUCTION	5
A. OVERVIEW	5
B. ORIGINS OF HISTOPATHOLOGY	8
a) Diagnostic or Forensic Pathology	8
b) Teratology	9
c) Predictive Pathology	9
d) Experimental Pathology	10
IV. LITERATURE REVIEW	11
A. HISTOPATHOLOGICAL CHANGES SEEN IN FISH TISSUES AND THEIR RELATION TO EXPOSURE TO METALS	11
1. <i>Introduction</i>	11
2. <i>Important points to Remember</i>	11
3. <i>Histopathological Alterations caused by Metals</i>	12
a) Gills.....	12
b) Liver.....	14
c) Kidney.....	15
d) Ovaries and Testes	16
e) Intestine.....	17
f) Skin.....	17
g) Muscle Cells	18
h) Olfactory Epithelium	18
4. <i>Tables</i>	19
V. HISTOPATHOLOGY: CRITICAL COMMENTARY	70
A. FISH HISTOPATHOLOGY - LABORATORY APPROACHES	73
1. <i>Diagnostic Methodology</i>	73
a) Overview	73
b) Temporal Change.....	73
c) Judgment and Diagnoses	74
2. <i>Fish histopathology methodology</i>	74
a) Sampling	74
b) Preservation	75

c) Sampling in the Field	75
d) Submission of Specimens	76
e) Preparing the Sample for Shipping.....	76
f) Shipping the Sample	77
3. <i>The Process of Evaluation</i>	77
a) Evaluation of Samples.....	77
b) Processing of Samples	77
(1) Tissues.....	77
(2) Whole Specimens.....	78
c) Reading the Slides.....	78
4. <i>Training</i>	78
5. <i>Quality Assurance</i>	79
6. <i>Dose-Response Relationships</i>	79
a) Toxicokinetics	79
(1) Absorption.....	79
(2) Distribution.....	80
(3) Metabolism/Biotransformation.....	80
(4) Excretion/Elimination	80
b) Responses.....	81
c) Mixtures	82
7. <i>Predictive Value</i>	82
a) Contaminant.....	82
b) Outcome.....	83
B. FISH HISTOPATHOLOGY - FIELD APPROACHES	83
1. <i>Diagnosis</i>	84
2. <i>Monitoring</i>	84
3. <i>Sensitivity</i>	85
4. <i>Specificity</i>	85
5. <i>Best Use</i>	85
C. RELATIONSHIP OF HISTOPATHOLOGY TO OTHER BIOMARKERS.....	86
D. DATA GAPS	87
1. <i>Experimental</i>	87
a) Morphological pathology	87
b) Clinical Pathology.....	88
c) Teratology	88
2. <i>Field Studies</i>	88
VI. UTILITY OF HISTOPATHOLOGY.....	89
A. RATIONALE FOR WHEN TO USE HISTOPATHOLOGY.....	89
1. <i>Diagnostic Assessment of Fish Kills</i>	89
2. <i>Defining the Dose-Response in Experiments</i>	89
3. <i>Field Studies</i>	90
B. WHEN HISTOPATHOLOGY IS OF LITTLE USE	90
C. APPROACHES TO HISTOPATHOLOGY	91
D. THE LIMITATIONS OF PATHOLOGY	91
1. <i>Temporality</i>	91
2. <i>Structure and Function</i>	91
3. <i>Relating Morphological Changes to Causes</i>	92
4. <i>Concurrent Disease</i>	92

5. <i>Confounding Variables</i>	93
E. ADVANTAGES VS. DISADVANTAGES OF HISTOPATHOLOGY	93
F. PRACTITIONERS AND AVAILABILITY	96
G. COSTS AND QUALITY ISSUES.....	97
1. <i>Preparation of Specimens</i>	97
2. <i>Number of Specimens Required</i>	97
3. <i>Transport of Specimens</i>	98
4. <i>Cost</i>	98
5. <i>Response Time and Reporting</i>	98
H. OPTIMIZING HISTOPATHOLOGY	98
I. THE USE OF FISH HISTOPATHOLOGY IN FILLING DATA GAPS	98
J. WHAT CAN BE LEARNED FROM THE ANALYSIS	99
VII. CONCLUSIONS.....	98
VIII. RECOMMENDATIONS.....	99
A. RECOMMENDED LEVEL OF ACTION:	99
B. HISTOPATHOLOGY AS A TOOL FOR THE MINING INDUSTRY	99
IX. BIBLIOGRAPHY	100
A. GREY LITERATURE:.....	100
B. JOURNAL ARTICLES:.....	108
X. GLOSSARY	140
A. PATHOLOGICAL TERMS USED.....	140
XI. APPENDIX	A-1
TECHNICAL EVALUATION OF HISTOPATHOLOGY - GOLDER ASSOCIATES.....	i

LIST OF TABLES

TABLE 1: HISTOPATHOLOGICAL EFFECTS DUE TO METALS	19
TABLE 2: HISTOLOGICAL EFFECTS WITH RESPECT TO FISH ORGANS	24
TABLE 3: HISTOPATHOLOGICAL LESIONS OF DIAGNOSTIC SIGNIFICANCE WITH RESPECT TO POLLUTANTS	33
TABLE 4: NONSPECIFIC HISTOPATHOLOGIC LESIONS WITH RESPECT TO POLLUTANTS	37
TABLE 5: THE ADVANTAGES, DISADVANTAGES AND LIMITATIONS OF FISH HISTOPATHOLOGY	93

LIST OF FIGURES

FIGURE 1: LEVELS OF BIOLOGICAL RESPONSE IN FISH TO POLLUTANT STRESS ILLUSTRATING THE CONTINUUM OF THESE RESPONSES ALONG GRADIENTS OF RESPONSE TIME AND TOXICOLOGICAL AND ECOLOGICAL RELEVANCE.....	71
---	-----------

DISCLAIMER

*This document was prepared by **GLOBALTOX INTERNATIONAL CONSULTANTS INC.** for the account of CANMET. The material herein reflects **GLOBALTOX**'s best judgement in light of the information available at the time of preparation. Any use which a third party makes of this report, or any reliance on or decisions to be made based on it, are the responsibility of such third parties. **GLOBALTOX INTERNATIONAL CONSULTANTS INC.** accepts no responsibilities for damages, if any, suffered by any third party as a result of decisions made or actions based on this report.*

I. EXECUTIVE SUMMARY

A. Summary

This paper provides a technical evaluation of histopathology as a monitoring tool for the mining industry in Canada, and addresses its role in the determination and monitoring of fish health impacted by those activities. Initially, the paper gives the reader some background concerning diagnostic methodology, the importance of judgment in the process of making a diagnosis, and the effects of temporality on interpretation. Pathology is described in general terms, and the differences between diagnostic or forensic, predictive, experimental, and toxicologic pathology are outlined. Next, the literature review of histopathologic changes in relation to metals and fish organs addresses pathological changes that may be observed using either a light microscope (i.e., a dissecting or normal light microscope), a scanning microscope or an electron microscope.

The methodology for fish histopathology is outlined, including sampling, preservation, submission of specimens and preparation of the sample for shipping, for field and laboratory studies. Histopathology is used in the field in an attempt to define the cause of death in fish die-offs and to define the specific nature of disease patterns so that temporal-spatial comparisons can be made. The process entails evaluation of samples, processing of samples, and reading the slides. The training of the pathologist takes many years and is important in the evaluation process. Comments are made concerning the necessary training for general pathologists and research morphologists, and how the correct training can prevent erroneous results. The importance of training for pathologists and morphologists is emphasized with respect to interpretation and standardization of diagnoses.

Quality assurance in histopathological studies occurs at two levels: Slide preparation and pathological interpretation. Dose-response relationships are necessary to predict *a priori* the likely outcome of exposure to a specific contaminant. The predictive value of histopathology varies from good to excellent in determining the health outcome; however, nothing is more predictive than pathognomonic lesions.

Data gaps encountered in experimental and field studies should be addressed. It is recommended that the determination of organ effects due to metals should encompass as many species as possible and exposure to a wide range of metals at different concentrations. Fish histopathology has a bias toward the effects of metals on gills compared to effects on other organs.

Histopathology, as a tool, has several limitations. Pathology is examined at only one point in time and therefore the changes described are limited to the tissue supplied. Morphological

changes can be seen only when the adaptive resources of the fish are exceeded. The relationships of structure and function, adaptation and disease, altered morphology and cause(s), influence(s) of concurrent disease(s), and other confounding variables are given to set the stage for what can be learned using proper collection and preservation techniques.

The report concludes with the recommendation that histopathology be considered in the following circumstances:

- to be used as routine diagnostic assessment technique in the case of fish die-off;
- to help define the background (or baseline) health status of the population;
- to be used in defining the No Adverse Effect Level in laboratory studies on effluent and leachates;
- to be used in operational and post-closure studies only in situations where there are histopathological data present; and,
- not to be used alone.

In conclusion, histopathology is a tool that has not been evaluated fully in monitoring the effects of the mining industry on the health or disease status of fish populations.

B. Résumé

Ce rapport présente les résultats d'une évaluation technique entreprise dans le but d'évaluer l'utilité de l'histopathologie comme outil de surveillance environnementale pour l'industrie minière du Canada et met en évidence le rôle que peut jouer cet outil dans la détermination et le suivi des effets des activités minières sur la santé des poissons. Le lecteur trouvera dans ce rapport des informations de base concernant les méthodes diagnostiques, un exposé sur l'importance du jugement dans l'établissement d'un diagnostic et une analyse des effets des fluctuations temporelles sur l'interprétation. La science qu'est la pathologie y est décrite en termes généraux, et des distinctions sont établies entre la pathologie diagnostique ou judiciaire, la pathologie prédictive, la pathologie expérimentale et la pathologie toxicologique. Dans une autre section, une étude de la documentation consacrée aux changements histopathologiques observés au niveau des organes des poissons en cas d'exposition aux métaux renseigne le lecteur sur les changements pathologiques qui peuvent être détectés à l'aide d'un microscope optique (ou microscope à dissection) ou d'un microscope électronique à balayage.

Les méthodes d'examen histopathologique applicables aux poissons sont décrites, et des informations complémentaires concernant l'échantillonnage, la conservation et l'expédition de spécimens et la préparation des échantillons en vue de leur expédition ou de leur utilisation dans le cadre d'études en laboratoire ou sur le terrain sont présentées. Sur le terrain, l'examen histopathologique peut aider à cerner les causes de mortalité massive chez le poisson et à suivre l'évolution de maladies spécifiques et favorise ainsi la réalisation de comparaisons spatio-temporelles. Cet exercice nécessite une bonne expérience de l'évaluation et du traitement des échantillons et de l'examen des lamelles. Il faut plusieurs années pour former un pathologiste, et la formation joue un rôle crucial dans le processus d'évaluation. Des observations sont faites concernant la formation qui doit être dispensée aux pathologistes généralistes et aux chercheurs spécialisés en morphologie, compte tenu du fait qu'une formation appropriée contribue à réduire les risques de résultats erronés. L'importance de bien former les pathologistes et les morphologues et les avantages qui en découlent au plan de l'interprétation et de la normalisation des diagnostics sont mis en valeur.

L'assurance de la qualité intervient à deux étapes de l'examen histopathologique, soit lors de la préparation des lamelles et de l'interprétation des résultats des examens pathologiques. Il est nécessaire d'établir des relations du type dose-réponse pour prévoir *a priori* les conséquences probables de l'exposition à un contaminant donné. La valeur prédictive de l'histopathologie en ce qui a trait à la détermination des effets sur la santé varie de bonne à excellente. Cependant, aucune variable ne recèle autant d'informations prédictives que les lésions pathognomoniques.

Dans les études expérimentales et les études sur le terrain, le manque de données constitue un problème important qu'il convient de résoudre. Pour la détermination des effets de l'exposition aux métaux sur les organes, il est recommandé d'exposer le plus grand nombre d'espèces possible au plus large éventail possible de métaux et de concentrations. La majorité des études histopathologiques consacrées à ce jour aux effets de l'exposition aux métaux sur les organes des poissons ont accordé une attention beaucoup plus grande aux branchies qu'aux autres organes.

Utilisée à des fins de surveillance environnementale, l'histopathologie comporte plusieurs limites. Les conclusions de l'examen pathologique ne sont valables que pour un moment bien précis, et les changements observés ne s'appliquent qu'à l'échantillon de tissu examiné. Les changements morphologiques deviennent évidents seulement lorsque la capacité d'adaptation des poissons est dépassée. Les relations entre la structure et la fonction, la capacité d'adaptation et la maladie, l'altération de la morphologie et les causes, l'incidence des maladies concomitantes et d'autres variables confusionnelles sont examinées afin d'illustrer les leçons qui peuvent être tirées d'une utilisation appropriée des méthodes de prélèvement et de conservation des échantillons.

Eu égard aux informations présentées ci-haut, l'utilisation de l'histopathologie comme outil de surveillance environnementale est recommandée uniquement aux fins suivantes ou en présence des conditions suivantes :

- évaluation diagnostique en cas de mortalité massive de poissons;
- évaluation de l'état de santé normal d'une population donnée;
- détermination en laboratoire de la concentration d'un composé choisi (dans un effluent ou un lixiviat) ne provoquant aucun effet indésirable;
- évaluation des effets d'un type d'exploitation donné ou de la fermeture d'une entreprise, mais uniquement en présence de données histopathologiques;
- toujours en combinaison avec d'autres outils de surveillance environnementale.

En conclusion, la valeur de l'histopathologie comme outil de suivi des effets des activités minières sur la santé (ou la morbidité) des populations de poissons demeure à évaluer de façon approfondie.

II. SCOPE OF THIS REVIEW

A. *Terms of Reference*

GLOBALTOX INTERNATIONAL CONSULTANTS INC. was retained by the Canada Centre for Mineral and Energy Technology (CANMET) to provide a technical evaluation of histopathology as an environmental monitoring tool for the mining industry in Canada. The following background and terms of reference were provided:

1. **Background:**

The Aquatic Effects Technology Evaluation (AETE) program was established to review appropriate technologies for assessing the impacts of mine effluents on the aquatic environment. AETE is a co-operative program between the Canadian mining industry, several federal government departments and a number of provincial governments; it is coordinated by the Canada Centre for Mineral and Energy Technology (CANMET). The program is designed to be of direct benefit to the industry, and to government - it will evaluate and identify technologies to meet environmental monitoring requirements, at the lowest cost. The program includes three main areas: acute and sub-lethal toxicity testing, biological monitoring in receiving waters, and water and sediment monitoring.

The program will conduct field evaluations of biological monitoring technologies to be used by the mining industry and regulatory agencies in assessing the impacts of mine effluents on the aquatic environment. It will also recommend specific methods or groups of methods that will permit accurate characterization of environmental impacts in the receiving waters in as cost-effective a manner as possible. A pilot field test was conducted in 1995 to fine-tune the study approach. In 1996, pre-survey activities were carried out at seven mine sites across Canada. The field evaluation of selected monitoring methods will then take place at a number of these mine sites in 1997.

One of the methods selected for potential field evaluation is the use of histopathology of fish tissues as an indicator of effects from mining activities. The AETE Technical Committee recommended that a technical evaluation on the use of histopathology be conducted prior to the 1997 field study.

2. Objectives:

The objective of this project was to conduct a technical evaluation of fish histopathology and make recommendations on its use as a cost-effective monitoring tool for the Canadian mining industry.

The technical approach was to provide scientific justification/rationale for the field evaluation of histopathology and provide essential information on its use for consideration in the design of the field study. The technical evaluation was to include a chapter which screens histopathology against a number of criteria and was completed by **Golder Associates Ltd.**

3. Task 1: Literature Review

- The contractor reviewed and summarized the literature (including gray literature) on the use of histopathology in environmental monitoring programs by:
 - Providing a description of the tissues and organs used in fish histopathology analysis and explaining the significance of the observed changes in these tissues;
 - Providing a referenced overview of the histopathology observed in fish due to exposure to specific metals;
 - Providing a critical commentary on the literature reviewed;
 - Providing examples of the use of histopathology for environmental monitoring, with a specific emphasis on environmental monitoring of mining impacts, and critically evaluating the success of these histopathology results in understanding environmental effects;
 - Identifying and briefly discussing the methods used (including a description of Quality Assurance/Quality Control issues, concerns, existence or need for protocols), professional training required to conduct the work, and approximate cost ranges for tissue examinations (including an explanation of the costs); and
 - Identifying research needs and gaps.

4. Task 2: Assess Possible Uses and Benefits of Histopathology

- The contractor provided a description of the utility of histopathology by:
 - providing the rationale for when histopathology would be an appropriate tool for the evaluation of mine impacts on fish health;
 - identifying situations where histopathology is unlikely to provide useful information in evaluating mine impacts on fish health;

- discussing different possible approaches to histopathology, identifying situations best suited to each level of analytical detail;
 - discussing the types of insights, and their limitations, which can be expected to result from histopathological analysis of fish;
 - highlighting the advantages, disadvantages and limitations of the technique for the mining industry context and summarizing these findings in a table;
 - describing the commercial availability of the technique, including the availability of qualified practitioners, transferability of expertise to the consulting industry and any other factors which may be a barrier for the successful implementation of the technique;
 - evaluating and documenting the cost implications of histopathological methods (with particular emphasis on commercial costs) and contrasting these to alternatives, such as the use of biomarkers; and
 - describing how histopathology can fill data gaps and complement the other analytical tools employed in evaluation of mine impacts on fish health.
- The contractor made recommendations on the use of histopathology as a cost-effective monitoring tool for the Canadian mining industry. The recommendations encompass the following aspects:
 - a recommended level of action (e.g. in carrying out a monitoring program, histopathology should be used in the first steps, as a trigger, or in more detailed information gathering stage); and
 - the best use of the tool within an overall monitoring strategy (including baseline, operational and post-closure) for the mining industry.
 - The contractor made recommendations, based on the information evaluated for this report, on the need to conduct field evaluations of histopathology (and, if relevant, the scope of the field work) as it potentially applies to the mining industry.
 - The contractor provided an annotated bibliography of the literature describing existing studies on the use of histopathology related to aquatic effects of mining.
 - The contractor provided a bibliography of the literature reviewed and a glossary of terms.

5. Task 3: Critical Evaluation of Histopathology as a Monitoring Tool

- A sub-contractor (Golder Associates Ltd.) critically evaluated the usefulness of histopathology, based on the contractor's written report for Tasks 1 and 2, as a cost-effective monitoring tool, compared with other environmental effects monitoring techniques against a set of criteria (including the following):
 1. Relative sensitivity (dose-response)
 2. Ecological relevance (predictive capability of effects and warning systems)
 3. Validation (peer-reviewed, field and laboratory)
 4. Site specificity
 5. Applicability
 6. Repeatability
 7. Chemical specificity
 8. Practical limitations for carrying out field work
 9. Commercial availability
 10. Response time (exposure, rapidity of response)
 11. Interpretability (statistical evaluation, confidence, clarity)
 12. Variability (temporal, spatial representativeness, sampling effort and variance)

- The sub-contractor also made a recommendation on the need for (and, if relevant, the scope of) field evaluation of histopathology at mine sites in Canada.

- The sub-contractor submitted this evaluation and the detailed results of the screening, in the form of a written Chapter, to the contractor for inclusion in the main report.

III. INTRODUCTION

Pathology can be considered the morbid anatomy of the biology of disease. The study of the biology of morphological alterations is aimed at evaluating the associations between lesions and their causes. Altered morphology, or structure, is the expression of the disease process that is evaluated. Histopathology is the histomorphological evaluation of microscopic alterations seen in diseased organs and tissues. As with gross pathology, where morbid anatomy is evaluated, histological changes are similarly evaluated for disease process, degree, distribution, and time.

Histopathology of fish is not used as a standard tool in aquatic environmental effects monitoring. As histopathology is considered for inclusion as a viable tool for determining fish health, the question arises as to whether this method of evaluation is a cost-effective method of increasing the knowledge base concerning the aquatic effects of the mining industry. The logistics of histopathology use, the training of those undertaking the evaluation, and the precautions in specimen preparation will be detailed in the following report. In addition, the strengths and weaknesses of this tool will be addressed highlighting when best to use this tool and how to optimize specimen collection. Finally, practical recommendations concerning the use of histopathology in the field will be outlined.

A. Overview

Altered morphology, or altered structure, is the expression of the disease process that is examined by the pathologist. Histopathology is the microscopic evaluation of these disease processes (Ferguson, 1989; Meyers and Hendricks, 1985; Klontz, 1985; Hayes, 1994; Haschek and Rousseaux, 1997). The point where histopathology commences and gross pathology finishes is variable, so for the purpose of the following discussion, the definition of histopathology will be: *'the evaluation of visual pathologic changes requiring the use of a microscope.'* Histopathology is both a science and an art. It is a very powerful, subjective tool which may be used to establish primary and secondary disease patterns in populations of fish. Most biomarkers are narrow in their expression (e.g., an enzyme) whereas pathology is broad in its evaluation (Moeller, 1985). Because of its broad scan and subjective nature, the practitioner must be experienced so as to filter out background visual "noise" such as seasonal liver changes (Moeller, 1985). However, positive diagnostic histopathological findings can be considered the quintessential biomarker, as not only does histopathology indicate exposure to certain environmental substances, it also shows the biological effect of exposure (Rousseaux *et al.*, 1995). In addition, pathology aids the biologist in establishing

population dynamics such as body condition, reproductive state, background disease and habitat effects (Ferguson, 1989; Adams *et al.*, 1996; Teh *et al.*, 1997).

Pathology, often thought to be limited to obtaining a diagnosis, is often overlooked as a measurement tool (Segner *et al.*, 1990; Evans *et al.*, 1991). By working closely with the research scientist or biologist, a pathologist can shed light on unseen biological processes that may be overlooked when using clinical, biochemical and toxicological endpoints alone. In addition, the pathologist can generate quantitative measurements to evaluate a known toxicological response, particularly following a dose-response exposure in the laboratory (Tones and Rousseaux, 1992). Early and integrated use of pathology can hasten the understanding of the disease process and increase the diagnostic acumen of the investigator (Rousseaux, 1988; Rousseaux, 1989).

There are advantages to using pathology in a failed 96-hr lethality study. For example, pathologists can look at a disease process and often determine the cause of death (Reichenbach-Klinke, 1973; Klinkelin *et al.*, 1985; Ferguson, 1989; Roberts, 1989; Ellis, 1985; Ribelin and Migaki, 1975; Hinton *et al.*, 1987). By matching the lesions (pathology seen) with the known toxicants in the test water, incrimination of one or more of the compounds can be attained (Tones and Rousseaux, 1992). Fish are often found dead in the tank and the investigation ceases there. In this situation, further histopathological investigation may reveal the cause of death. In addition, a pathologist can examine a disease process at various points in time, or can identify endemic diseases in populations in question (Schultz, 1980; Slauson and Cooper, 1990). In the case of baseline studies, observations can be compared with future observations to determine whether industry has affected the population adversely with respect to health. By undertaking this procedure at an early stage, industry can avoid blame for "causing disease" (endemic disease) in the eye of the public. Secondly, the nature of disease in a wild population may be multifaceted (Moeller, 1985; Ferguson, 1989; Roberts, 1989). As overt toxicity may not always be obvious, examination of prevalence and degree of a disease, such as parasitism, in the population may give clues as to whether the population is under stress or is being immunosuppressed (Kerr and Dickie, 1984).

Specific compounds may cause characteristic, and sometimes unique, changes in structure. These changes are known as pathognomonic changes, i.e., the morphological diagnosis defines the disease (Thomson, 1984). In the case of field surveys, the pathological changes seen may not be characteristic of a particular contaminant, but may be due to the "stress" caused by the contaminant resulting in secondary disease. By evaluating the tissue loads of

metals and enzyme/protein concentrations (e.g., metallothionein) and evaluating pathology at a number of sampling times or in a number of places, it may be possible to obtain more information concerning temporal and spatial associations by correlating these variables (Lilienfeld and Lilienfeld, 1980). For example, comparison of a baseline study with a study done after operations are in progress may fail to show an effect of the industry on the disease prevalence, although tissue metal loads and metallothionein concentrations may be elevated.

Without data to show a temporal association between mine operation and observed pathological effects, it would not be possible to conclude that a mine had an effect on the population from a disease perspective.

Pathology is also useful in describing dose-response relationships to contaminants (Hinton and Lauren, 1990a). It should be noted, however, that statistically significant differences found between treatment groups do not necessarily mean that there is a biologically significant difference between body tissues (Bucci, 1991). This means that when a statistically significant difference occurs in the biomarker in question, there is further need to decide whether these differences are of biological importance. For example, in order to determine whether a statistically significant group difference in red cell numbers is of biological importance, it is necessary to establish whether these numbers lie within the normal range and whether the hemopoietic tissue is producing the correct number of cells.

There are a number of limitations of pathology, and these are as follows:

- Not all disease processes have histopathological endpoints, e.g., acute hypoxia (lack of oxygen);
- It takes time for histopathological changes to develop, so the fish may die before histopathology has developed;
- Not all toxic insults produce toxicant-specific responses;
- Evaluation of morphology is subjective and dependent on the previous experience of the examining pathologist, hence operator bias may occur. In the case of a baseline study, it is always wise to re-read the initial slides and compare them with the second sampling. By doing this, a true comparison of the effects of time may be attained;
- Cause and effect relationships are difficult to demonstrate for many contaminants as often the histopathology seen is similar for a number of contaminants;
- There are few qualified individuals skilled in fish tissue preparation and pathological evaluation;
- Histopathological changes cannot necessarily be used to infer a population-level effect in fish; and,

- Errors can arise from inadequate prior knowledge of the “normal” state for a given species. There is tremendous natural variation for specific tissues at different times of the year.

For the above reasons it can be seen that the client and other scientific team members require guidance as to how to use their limited budgets wisely on pathology.

B. *Origins of Histopathology*

To understand the present state of histopathology, it is useful to review its origins (Rousseaux, 1997). Pathology, which includes gross, subgross, light microscopic and ultrastructural morphologic evaluation of disease processes (Cotran *et al.*, 1989), began as a science of observation, which emphasized narrative descriptions of lesions, and which gradually evolved as associations were made between lesions and their causes. Pathology grew as a discipline out of medicine at a time when the field of medicine was just emerging as we know it. Thoughts as to causation and treatment were based on dogma, rather than evidence. Rapidly following the discovery of the microscope, “cellular pathology” was defined as the basis of modern pathology and medicine (Cheville, 1983). This concept is still the basis of morphologic pathology and can be considered the prevailing dogma. Even today pathologists learn the trade through apprenticeship, and all would agree that experience in the necropsy room and at the microscope is an essential requirement for a successful practice (Thomson, 1984; Thomson, 1988).

Initially, the focus of pathology was anthropocentric; however, as animal disease became important from a commercial and human health perspective, veterinary pathology was born. More recently, pathologists have looked into comparative diseases across species resulting in the discipline of comparative pathology (Ashley, 1975). It is out of this last group that aquatic pathologists have developed a specialty (Ferguson, 1989; Roberts, 1989; Bryden, 1988). As biologists have given us excellent works on the histology of fish (e.g., Groman, 1982), both biologists and pathologists have a reasonable “tissue base” to work from. However, at present the *a priori* use of histopathological evaluation is in its infancy. Because of this, there is little background literature available from peer-reviewed sources concerning the prediction of the impact of mining contaminants on fish in a natural habitat down stream, although some data are available for other contaminants (Ribelin and Migaki, 1975; Johnson and Bergman, 1984; McCarthy and Shugart, 1990).

a) *Diagnostic or Forensic Pathology*

Initially, this diagnostic tool was forensic in nature, relying on previous events that probably lead to a cause of death. It can be regarded as a diagnostic tool linking lesions and etiologies

(cause of disease or identification agents causing the changes). Diseased states can be recognized based on the structural lesions present (Thomson, 1984; Thomson, 1988; Jubb *et al.*, 1985; Cotran *et al.*, 1989). A definitive diagnosis is made by eliminating alternative diagnoses, sometimes through further clinical and laboratory evaluations. The process of making a diagnosis is judgmental, rather than stochastic, and hence requires considerable experience and training (Hill and LaVia, 1980). Diagnostic pathology is a very useful tool to evaluate the cause of death in fish, provided that the fish have not been dead for long, as toxicologically-induced lesions cannot always be differentiated from postmortem degeneration within six hours of death (Rousseaux *et al.*, 1990). It should be noted that dead fish do not always reveal their assailants. Diagnostic pathology aims at pinpointing the cause of the morphological alterations seen, i.e., who, what, when, where and why did the fish die?

b) Teratology

Teratology is a discipline that has its roots in experimental embryology (Taylor, 1986). Teratology, the study of defective development, or terata, has only been formalized for the last three decades. The thalidomide disaster that affected many children of women given the tranquilizer led to the establishment of detailed morphological evaluation of affected children and the creation of regulations to test materials in animals for their teratogenic, or birth defect causing potential (Wilson and Fraser, 1977; Rousseaux and Blakley, 1991). Defective development is another useful endpoint to evaluate, as many defects result in death of the affected individual either directly by causing mortality or indirectly by decreasing survivability in a competitive environment. These methods have been used to evaluate the effects of polluted rivers on the development of lake sturgeon eggs (*Acipenser fluviensis*) (Branchaud *et al.*, 1995), and the effects of dithiocarbamates and related compounds (Van Leeuwen *et al.*, 1986). The microscopic evaluations and specimen preparation methods such as the Wilson freehand sectioning technique (Wilson and Fraser, 1977) and the dual staining of cartilage and bone (Rousseaux, 1985) have not routinely been used in aquatic histopathology. However, the low expense and large amount of data that can be gained from the evaluation of fry through these methods warrants further evaluation as a tool to measure the biological effects of contaminant exposure.

c) Predictive Pathology

This assessment, which is used for *a priori* prediction (risk assessment) of adverse effects of chemicals and pollutants, required the rigors of science. This change from forensic to predictive pathology resulted in the necessary scientific understanding to quantify alterations and to evaluate temporal changes for prognostic purposes (Rousseaux, 1997). An extension of this understanding lies in the utility of pathology for evaluating temporal patterns of

disease as these changes can be quantified (Evans *et al.*, 1991). Unfortunately, there is a dearth of useful histopathological data and no teratological data in the literature concerning baseline studies with respect to the mining industry, which makes evaluation of this technique difficult.

d) *Experimental Pathology*

The field of experimental pathology differs from the mainstream diagnostic pathology in that evaluation of tissues is used as a scientific tool following deliberate exposure of an animal to a known toxicant, toxin, or infectious agent. Here, judgment may be used, but more commonly, the lesions are identified and graded using a blinded technique to reduce subjectivity. Identification of exposure-related changes in morphology is important in the risk assessment process (Brecher, 1997), and it is in this area that most scientifically trained histomorphologists work. In fact, the experimental pathologist quantifies changes so that a dose-response curve can be created and no observable adverse effect concentrations (NOAEC), or no effect concentrations (NOEC), can be determined for specific toxicant-tissue reactions (Hayes, 1994; Klaassen, 1996). These values can then be used for regulatory purposes.

IV. LITERATURE REVIEW

A. *Histopathological Changes Seen in Fish Tissues and their Relation to Exposure to Metals*

1. Introduction

This document is concerned with the evaluation of pathology using either a dissecting or light microscope. It should be noted that other forms of morphological evaluation are available, and can be used if resources permit. Ultrastructural cellular pathology refers to changes seen at the cellular level as viewed by scanning or transmission electron microscopy (Porter and Bonneville, 1973; Cheville, 1983). These methods are too labor intensive and expensive to be used in any other situation than experimental or research situations. The following critical review addresses pathological changes seen using a light microscope (either a dissecting or normal light microscope). If data are available for ultrastructural evaluation, they are included for completeness. It is understood that a gross evaluation would be performed and recorded in the field.

2. Important Points to Remember

Literature concerning the histopathology of toxicant-induced changes in fish is not as plentiful as that available for mammals (including humans). The peer-reviewed literature represents a mixture of recorded data and opinion. This opinion is subject to the dogma of the day, and that differing dogma between the aquatic biology schools and the comparative pathology schools may lead to peer-reviewed opinions that do not agree.

Materials that are available are mainly generated in an experimental setting, and as such may be difficult to extrapolate to the field situations, where concurrent disease usually impacts the individual. In addition, it is important for the reader to bear in mind the following points:

- Terminology used in histopathology is often not standardized. In the field of comparative pathology there have been efforts made to standardize the nomenclature used with respect to specific lesions (SSNDC, 1997). Disagreement amongst pathologists may occur when describing the most important event at the tissue site. This has led to many regulatory bodies insisting on the establishment of pathology working groups to standardize terminology, especially in the case of some drug-induced lesions in rodents (Hildebrandt, 1991). More importantly, there are multiple terms used to describe the same disease processes. For example, a simple scar can be described as: organization,

fibrosis, mesenchymal proliferation, stromal proliferation and scarring (Thomson, 1984);

- Lesions of histopathology take time to develop. These range from a couple of hours (gills) to days (bone), and as such, temporality is important with respect to lesion evaluation (Slauson and Cooper, 1990);
- Evaluation of the tissue is done using a thin slice of stained tissue (usually 4-6 μm in thickness). This means that if multiple sections have not been taken, or if the disease process is focal, information may have been missed (Bucci, 1991);
- Evaluation of disease processes is subjective, and, therefore, without a second opinion or photographic evidence can be considered anecdotal in nature (Hildebrandt, 1991); and,
- Often the specific tissue in question is evaluated without consideration to changes in other tissues, thus leaving data gaps (Dodd, 1991; Ruben and Rousseaux, 1991).

Environmental pollutants, and other disease causing agents, act through a finite number of pathogenic pathways to produce a finite number of histopathological changes (Kyle and Farber, 1991). There are, however, some situations where pathognomonic changes are characteristic of poisoning by a specific metal leading to the comment that histopathology is the most rapid method of detecting adverse acute and chronic effects of exposure in the various tissues and organs comprising an individual fish (Hinton *et al.*, 1992). The following is a review of the lesions (histopathological alterations) related to metals and other materials associated with the mining industry.

3. Histopathological Alterations caused by Metals

a) Gills

The gills of the brown bullhead, *Ictalurus nebulosus* (LeSueur), exposed to experimental copper solutions of 5 ppm showed swollen and hyperemic lamellae, necrosis and disaggregation of the epithelium (Benedetti *et al.*, 1989). Gill damage at 0.3 ppm copper varied depending on individual stress, where gills of stressed specimens were very swollen and showed degeneration of the gill epithelium with focal necrosis.

Two species of teleosts, the zebrafish, *Brachydanio rerio*, and the rainbow trout, *Salmo gairdneri*, were exposed to different concentrations of cadmium and the gill morphology was assessed following 6 weeks of exposure (Karlsson-Norrgren *et al.*, 1985). At low cadmium

concentration of 3 µg /CdL, the minor changes in gill alterations in the chloride cells of the secondary lamellae were observed compared with that of the controls in zebrafish.

A morphometric study of the secondary lamellae of zebrafish, *Brachydanio rerio* (Hamilton-Buchanan), and rainbow trout, *Salmo gairdneri* (Richardson) revealed an increase in the portion of the secondary lamellae exterior to the basal lamina, resulting in an increased diffusion distance after exposure to cadmium concentrations of 10 -100 µg/L (Karlsson-Norrgren *et al.*, 1985). In contrast with control fish, treated fish showed curling of the secondary lamellae and finally local telangiectasia. The first sign of degeneration was observed in the chloride cells, which were characterized by dispersed cytoplasm and a smooth apical plasma membrane (electron microscopic evaluation).

Temminck *et al.* (1983) showed that hyperplasia of the gill epithelium was induced in fingerling rainbow trout (*S. gairdneri*) exposed to chromate at pH 6.5. The hyperplasia seems to result from direct chromate damage to the mucosal epithelium, triggering increased mitotic activity in underlying cells. In gills of treated fish, the number of mitoses was significantly higher in both primary and secondary epithelium than in control gills. Newly formed epithelial cells were observed to differentiate into chloride and mucus cells.

Microscopic examination revealed pathological changes in the gill filaments and respiratory lamellae of the mummichog *Fundulus heteroclitus* after 20 hr exposure to 50 ppm of cadmium (Gardner and Yevich, 1970). Histopathological evaluation showed necrosis and sloughing of respiratory filaments, hypertrophy of gill filaments, and hyperplasia of the epithelial surface of respiratory lamellae and interlamellar filament epithelium. The hyperplasia was accompanied by a marked increase in mitotic figures. Changes did not involve all gill filaments and were not localized to specific areas of the branchial arches. Lymphocytic infiltration, indicative of an inflammatory response, of the interlamellar filamental epithelium was evident in all animals with exposure beyond 20 hr.

Skidmore and Tovell (1972) studied the gills of zinc-poisoned rainbow trout *Salmo gairdneri* (Richardson) using light and electron microscopic evaluation. Changes that occurred in the gill tissue of rainbow trout exposed to 40 ppm zinc included lifting of the secondary lamellar epithelium. Blood flow patterns through the lamellae changed, followed by the appearance of granulocytes (inflammation) within the lamellar blood spaces and beneath the raised epithelium.

A morphological study of the gills of windowpane flounder *Scophthalmus aquosus* (Mitchill) exposed to 5 or 10 µg/L mercury for 60 days showed that the number of chloride cell apical pits and gill filaments bearing 'cratered' epithelial cells increased at the 5 µg/L level and decreased at the higher exposure level (Pereira, 1988). Focal swellings demonstrated a dose-dependent relationship, their numbers being greater at the 10 µg/L exposure level. The epithelial cells overlying the focal swellings demonstrated a fragmented microridge pattern. This change in microridge morphology may affect gill function through reduction of surface area, ridge-induced microturbulence of water, or adherence of mucus to the gills (Karlsson-Norrgren *et al.*, 1985).

After 1-3 days exposure to 0.5-1.0 mg zinc in distilled water, cytoplasmic abnormalities in sticklebacks *Gasterosteus aculeatus* (L.) consisted of extensive vacuolation, followed by swelling of nuclei and mitochondria leading to cellular disintegration as visualized using electron microscopy (Matthiessen and Bradfield, 1973). Recovery of acutely poisoned fish in zinc-free hard water permitted the regeneration of epithelia and the appearance of chloride cells on the secondary lamellae. The proliferation of chloride cells may indicate that chloride cells are produced as a direct or indirect response to the influx of zinc ions.

The significance of observed gill changes relates to the type of damage and the amount of gill surface affected. As the gills are the respiratory apparatus for most fish, diffuse damage can cause extreme respiratory distress by inhibiting oxygen transfer from the water into the blood stream. Multifocal, but severe, lesions can also reduce respiration through obstruction of the secondary lamellae by large amounts of exudate. Such an exudate is also an excellent growth medium for opportunistic pathogens, and may lead to secondary infections.

b) Liver

In a histopathological study of the effects of experimental copper pollution at high concentrations (5 ppm) and low concentrations (0.3 ppm) on bullheads *Ictalurus nebulosus* (Le Suer), analysis of livers exposed at either concentration did not reveal diffuse changes in the hepatic parenchyma (Benedetti *et al.*, 1989). However, the authors reported areas of patchy hepatic degeneration. Histochemical staining further demonstrated lower liver glycogen content than in the controls in all treatments, with scattered areas of normal and depleted glycogen content in the treated specimens.

A histopathology study in snake head fish *Channa punctatus* to the effects of 6.8 mg/L lead nitrate for 125 days, showed liver cord disarray, necrosis, inflammation of portal areas, hardening of connective tissue, shrinkage of nuclei, and septa formation around blood vessels (Sastry and Gupta, 1978b). No fatty infiltration or glycogen depletion was observed.

Treatment of snake head fish *Channa punctatus* with a sub-lethal concentration of lead nitrate produced considerable hepatic structural damage and decreased alkaline phosphatase and aminopeptidase activities.

The rate of change in hepatocyte ultrastructural morphology was observed following exposure to arsenic concentrations of 0, 30, or 60 ppm, and after exposure times of one, two, or three weeks at 20°C (Sorensen, 1976). Histopathological changes were more pronounced with an increase in arsenic concentration and exposure time. These changes included the appearance of electron dense particles (EDP) with a subsequent increase in the numbers of intra-nuclear and cytoplasmic electron dense particles and aberrant mitochondria. Cytoplasmic and intra-nuclear EDP were first observed in hepatocytes of green sunfish *Lepomis cyanellus* (Rafinesque) exposed for two weeks to a solution containing 30 ppm arsenic and for one week to 60 ppm arsenic. Also, lysosomes and smooth endoplasmic reticulum increased in number, while the number of myelin figures decreased.

A series of experiments by Sastry and Gupta (1978a) have shown that significant pathological changes were produced by 0.3 mg/L mercuric chloride in the liver of snake head fish *Channa punctatus* over a period of 30 days. Histopathological changes included hepatocellular granulation and vacuolation of the cytoplasm, hypertrophy of the nucleus, necrosis, fatty infiltration, proliferation of connective tissue, glycogen depletion and cirrhosis.

Dixon and Leduc (1981) studied the chronic cyanide poisoning of rainbow trout and its effects on growth, respiration and liver histopathology. Juvenile rainbow trout *Salmo gairdneri* (Richardson) exposed to concentrations of 0.01, 0.02, or 0.03 mg/L hydrogen cyanide for 18 days showed widespread degenerative necrosis of hepatocytes at all concentrations tested.

Hepatic damage has to be severe and diffuse to result in liver failure due to the large hepatic reserve (Ruben and Rousseaux, 1991). Liver toxicity does, however, result in altered fat metabolism, and digestion, thereby resulting in generalized stress of the fish (Klaassen, 1996).

c) *Kidney*

Pathological changes attributable to cadmium poisoning were observed in the kidney of mummichogs *Fundulus heteroclitus* after 12 hr exposure to 50 mg/L of cadmium (Gardner and Yevich, 1970). The damage appeared limited to the proximal tubules of the kidney. Many of the proximal tubules exhibited pink-staining granular casts with nuclear debris, and

others showed various stages of degeneration. The tubular deterioration and the non-involvement of collecting tubules and glomeruli in mummichogs *Fundulus heteroclitus* indicates a relation paralleled to that observed in higher vertebrate forms including humans.

Banerjee and Bhattacharya (1994) observed histopathological changes in the anterior and posterior kidneys of snake head fish *Channa punctatus* induced by 16.7 ppb mercuric chloride on 7, 28, 63, and 90 days exposure. Renal lesions consisted of minimal to mild multifocal acute tubular epithelial degeneration, karyolysis, and dilation or shrinkage of Bowman's capsule and glomerulus. Observations of epithelial cell necrosis in the posterior kidney may be correlated with uptake of mercury and rapid elimination phases.

Waite *et al.* (1990) histopathologically evaluated whitefish *Coregonus clupeaformis* and northern pike *Esox lucius* that were exposed to uranium mine tailings. Histological findings showed that there were no significant differences in muscle, kidney, intestine and pancreas changes between whitefish *Coregonus clupeaformis* and pike *Esox lucius*. The authors concluded that the concentrations of radionuclides and other heavy metals in the tissues and environment of Langley Bay whitefish had not caused histopathological changes in these fish.

Morphological kidney changes give the pathologist more specific information concerning the type and duration of toxicant exposure. Segmental nephron damage is characteristic of some compounds, as are intra-nuclear inclusions. Regenerative tubules are easily visualized *via* light microscopy, and give clues as to the duration of the exposure (Thomson, 1988). As the kidney contains a large amount of lymphoid tissue, this is an excellent opportunity for the pathologist to superficially view the immune system (Ferguson, 1989).

d) Ovaries and Testes

Nath and Kumar (1990) investigated the histological impact of sub-lethal concentrations of nickel on the gonads of both sexes of the freshwater tropical perch, *Colisa fasciatus*, following 96-hr exposure to 64 mg/L of nickel sulphate. Histological sections revealed degeneration of the germ cells in the testicular lobules, reduced spermatogenic activity, rupture of the testicular lobules and the appearance of interfollicular spaces due to the shrinkage of the oocytes.

Light microscopy of the ovaries and testes is the quintessential way to determine the maturity of the fish under examination. Eggs are well defined, and allow quantitative morphometry so that subtle changes in sizes and numbers can be quantified.

e) Intestine

Histopathological evaluation of the effect of cadmium on the intestinal tract revealed that the first detectable morphological changes occurred in mummichogs, *Fundulus heteroclitus*, one hour after exposure to 50 ppm of cadmium (Gardner and Yevich 1970). Cadmium exposure induced an increase in mucous cell activity and swelling of the intestinal epithelium. The severity of lesions increased with exposure time.

Sastry and Gupta (1978a) reported a hyperactivity of mucus secreting goblet cells and a release of large amount of mucus into the intestinal lumen, following the exposure of snake head fish, *Channa punctatus*, to 0.3 mg/L mercuric chloride for 5, 10, 15, 20 and 30 days. The authors also studied the effect of a sub-lethal concentration of 6.8 mg/L lead nitrate on the digestive system of snake head fish, *Channa punctatus*. The histological structure in the intestine and pyloric caeca after 125 days of exposure showed flattening of villi at a number of places, inflammation, and necrosis. In the study, enzymological changes were also noted. At the time of histopathological measurements, there was an increase of acid phosphatase in the intestine while aminotripeptidase and glycylglycine dipeptidase were inhibited (Sastry and Gupta, 1978b).

The intestine in all animals is affected by nutrition (Jubb *et al.*, 1985). Therefore, it is essential for the pathologist to evaluate intestinal villi, bearing in mind the nutritional status of the fish. The intestine can be directly, or indirectly affected by toxicants. The significance of these toxicant-induced changes include malabsorption, secondary parasitic infections, blood loss, and protein-losing enteropathies.

f) Skin

Brown bullheads, *Ictalurus nebulosus* (LeSueur), reared for more than a month in 0.3 ppm copper solution, showed epidermal changes histopathologically determined to be due to an increase in the number of epithelial mucus cells (Benedetti *et al.*, 1989). These mucus cells stained less intensely than controls, with Alcian blue, PAS (Periodic Acid Schiff), and Alcian blue-PAS, stains which are used to highlight mucus.

Examination of the skin surface morphology of air-breathing catfish, *Saccobranchus fossilis* (Bloch), exposed for seven days to 5.6 mg/L chromium revealed the accumulation of excess mucus, with active mucous cells having lost their hexa or polygonal shape (Khangarot and Tripathi, 1992). It is suggested that a molecular interaction occurs between mucus glycoprotein and toxic chromium ions. Focal necrosis and hypersecretion has often been observed in chromium-exposed mucus cells.

The significance of epidermal damage is two-fold: firstly, the loss of integrity allows for the establishment of opportunistic microbes on and within the fish; and secondly, this results in the loss of nutrients through exudation and excess mucus production.

g) Muscle Cells

In a study of the effects of experimental copper pollution on muscle in the larvae hatched from eggs of herring, *Clupea harengus* (L.), ultrastructural examination of the myocytes (muscle cells) revealed no difference from controls at 0.01 ppm copper (Abbasi *et al.*, 1995). In contrast, myocytes of larvae exposed to 0.03 and 0.05 ppm copper showed swelling of the mitochondria and sarcoplasmic reticulum, an increase in perinuclear space, a reduction in the myofibrils and in the volume of mitochondria and their cristae. As a consequence, the affected larvae were unable to swim and died of starvation due to an impairment of movement. These functional changes were associated with a reduction in myofibrils and sarcoplasmic reticulum disruption.

h) Olfactory Epithelium

Chakrabarti *et al.* (1993) investigated alterations in the microarchitecture and histology of the olfactory epithelium in the freshwater perch, *Anabas testudineus*. The microanatomical changes of the olfactory organ may prove to be reliable indicators of metal induced stress in fish exposed to a natural ecosystem. Severe histopathological changes following the exposure to a sub-lethal concentration of cadmium (26 mg CdCl₂/L for 70 days) included the fusion and disruption of ciliated structure in the free border epithelium, rupture of the receptor and supporting cells, damage of microvilli on the non-sensory epithelium and fragmentation of microridges of the stratified epithelial cells. The authors suggested that disruption and disarray of sensory receptor cells in the olfactory epithelium were most probably caused by cadmium toxicity. The most significant pathological changes were the necrosis of the cell boundaries of supporting and receptor cells culminating in clumping of nuclei, deterioration of the basement membrane, hypertrophy of the blood cells and mucus cells.

There are also reviews concerning the toxicity of zinc, copper, selenium, cadmium, and mercury, although the pathological descriptions are not very detailed.

The effect of damaged olfactory epithelium varies depending on the degree of damage. Mild damage may be of little relevance to the fish; however, severe damage may result in loss of ability to seek food. Damage to sensory tissue may also impact behavioral parameters linked to feeding and reproduction such as water temperature selection.

4. Tables

Table 1: Histopathological Effects due to Metals

HISTOPATHOLOGY	COMMENTS	REFERENCE
Chromium		
Gill epithelial necrosis, fusion, hypertrophy and hyperplasia	conducted in a laboratory; evaluation performed under light and electron microscopes; recovery experiments enabled to investigate the reversibility of the phenomenon.	Temmink <i>et al.</i> , 1983; Gill and Pant, 1987.
Necrosis and sloughing off of intestinal epithelium	conducted in a laboratory; evaluation performed under a light microscope; tissues were fixed in Bouin's fluid, prepared with paraffin for sectioning and stained with Harris's hematoxylin and eosin.	Fromm and Schiffman, 1958
Cyanide		
Decreased maturation of oocytes i.e. reduced vitellogenesis	conducted in a laboratory; evaluation performed under a light microscope.	Lesniak and Ruby, 1982
Reduced state of sperm development by damaging spermatogonia	conducted in a laboratory; evaluation performed under a light microscope; histological sections from control ovaries were used for establishing the six arbitrary stages of egg development based upon the diameter of the oocyte in combination with cytoplasmic and nuclear features and development of egg membranes and their associated follicular cells.	Ruby <i>et al.</i> , 1979
Degenerative lesions in liver	conducted in a laboratory; evaluation performed under light and electron microscopes; included evaluation of growth and metabolic rate; cyanide-exposed fish sustained reduced fat gains.	Dixon and Leduc, 1981
Lead		
Testes		Srivastava, 1987
Expanded tubular lumens, debris in lumens and reduced lymphoid tissue in	conducted in a laboratory; evaluation performed under a light microscope; fish were sectioned at eight	Crandall and Goodnight, 1963; Guo <i>et al.</i> , 1991;

HISTOPATHOLOGY	COMMENTS	REFERENCE
kidney	or 12 microns and stained with Delafield's hematoxylin and eosin.	
Degenerative changes in liver, intestine and pyloric caeca	conducted in a laboratory; evaluation performed under a light microscope.	Sastry and Gupta, 1978b; Bengeri and Patil, 1986
Arsenic		
Gill epithelial lifting, aneurysms, liver fatty infiltration and focal necrosis	conducted in a laboratory; evaluation performed under a light microscope; included assessments of the basis of survival, growth, hematocrit measurements, ratio of gonad weight to body weight, and pathological changes in tissues.	Gilderhaus, 1966
Hepatocyte alterations	conducted in the laboratory; evaluation performed under an electron microscope; both living and dead fish were examined.	Sorensen, 1976
Rupture of testicular lobules	conducted in a laboratory; evaluation performed under a light microscope; the testes was excised, washed and fixed in picro-mercuro-formol; paraffin sections (6-8 µm) were stained with Heidenham's iron hematoxylin.	Shukla and Pandey, 1984
Ammonium		
Cytoplasmic degeneration of liver cells, vacuolation and necrosis in gill epithelium	conducted in a laboratory; evaluation performed under a light microscope; tissues were preserved in Bouin's solution; sections were cut at 5 µm; internal organs, brain, gills, and thymus were preserved.	Smith and Piper, 1975; also see: Colt and Tchbanoglous, 1978; Dauba <i>et al.</i> , 1992; Mitchell and Cech, 1983; Pande and Pande, 1988; Ram and Sathyanesan, 1987; Robinette, 1976; Thurston <i>et al.</i> , 1986
Liver cell atrophy, fatty infiltration	conducted in a laboratory; evaluation performed under a light microscope; samples were embedded in paraffin and 6µm thick sections were stained with hematoxylin-eosin and Periodic Acid Schiff.	Wajsbroet <i>et al.</i> , 1993
Gill aneurysms, epithelial thickening	conducted in a laboratory; performed under a light microscope;	Smart, 1976

HISTOPATHOLOGY	COMMENTS	REFERENCE
	evaluation of acute & chronic toxicity.	
Nickel		
Gill edema (epithelial lifting), fusion of secondary lamellae	conducted in a laboratory; evaluation performed under an electron microscope; relative diffusing capacity was estimated; sections were examined under oil immersion at a magnification of 1413x.	Hughes <i>et al.</i> , 1979; also see: Nath and Kumar, 1989
Reduction of spermatogenesis, tubular degeneration and distension of testicular blood vessels	conducted in a laboratory; evaluation performed under light microscope; gonads were fixed in Bouin's solution; sections 4-6 µm thick were cut, processed and stained with hematoxylin and eosin.	Nath and Kumar, 1990
Selenium		
Proliferative glomerulonephritis and tubular necrosis	field experiment; under an electron microscope; environmentally- exposed fish were collected.	Sorensen <i>et al.</i> , 1982; also see: Sorensen, 1988
Hypertrophy and hyperplasia of exocrine pancreas	field experiment; under an electron microscope; environmentally- exposed fish were collected.	Sorensen <i>et al.</i> , 1983a
Centrilobular necrosis and increased phagocytic cells in liver	field experiment; under an electron microscope; environmentally- exposed fish were collected.	Sorensen <i>et al.</i> , 1983b
Zinc		
Kidney tubule dilation	conducted in a laboratory; evaluation performed under a light microscope; fish were sectioned at 8-12 µm and stained with Delafield's hematoxylin and eosin.	Crandall and Goodnight, 1963; also see: Brown <i>et al.</i> , 1968; Crespo and Sala, 1986; Leland, 1983; Lloyd, 1960; Sehgal and Saxena, 1986
Gill epithelial necrosis	conducted in a laboratory; evaluation performed under an electron microscope; following the experiment, recovery period assessed in zinc-free tap water.	Matthiessen and Bradfield, 1973
Desquamation of gill epithelium	conducted in a laboratory; evaluation performed under an electron microscope; electron micrographs displayed an increased number of	Skidmore and Tovell, 1972

HISTOPATHOLOGY	COMMENTS	REFERENCE
	granulocytes in the filamental sinus, and some lifting of the filament epithelium.	
Fusion of secondary lamellae detachment of epithelium from pillar cell system (epithelial lifting)	conducted in a laboratory; evaluation performed under a light microscope; also exposed to dehydroabietic acid (DHAA).	Tuurala and Soivio, 1982
Copper		
Heavy gill-mucus response	conducted in a laboratory; evaluation performed under a light microscope; exposure to cadmium and preliminary exposures to mercury, silver, zinc, and the chlorinated pesticide methoxychlor were tested.	Gardner, 1975; also see: Julliard <i>et al.</i> , 1993; Khangarot, 1992; Lanno <i>et al.</i> , 1987; Leland, 1983; Mount, 1968; Reimschuessel <i>et al.</i> , 1992; Saucier <i>et al.</i> , 1991
Cytoplasmic vacuolation and clumping of nuclear chromatin in proximal tubule cells	conducted in a laboratory; evaluation performed under a light microscope; fish were immersed in mixtures of Cd ²⁺ , Cu ²⁺ and Zn ²⁺ .	Eisler and Gardner, 1973
Kidney necrosis, fatty liver, gill cell vacuolation	conducted in a laboratory; evaluation performed under light and electron microscopes; effects of copper on liver, kidney and gills.	Baker, 1969
Gills swollen, necrotic and disaggregated patchy areas of degeneration of liver	conducted in a laboratory; evaluation performed under a light microscope.	Benedetti <i>et al.</i> , 1989
Cadmium		
Testicular hemorrhage and necrosis	conducted in a laboratory; evaluation performed under a light microscope; the length and weight of the body and testes were recorded; the testes in 4-6 µm sections were fixed in aqueous Bouin's fluid and embedded in paraffin.	Pundir and Saxena, 1990
Gill necrosis and sloughing of mucosa	conducted in a laboratory; evaluation performed under a light microscope; seawater-exposed mummichogs were used; differences in the histopathological responses of marine and freshwater-exposed mummichogs.	Voyer <i>et al.</i> , 1975; also see: Tanfanelli and Summerfelt, 1975; Ooi and Law, 1989; Oronsaye, 1989; Wilson and Taylor, 1993

HISTOPATHOLOGY	COMMENTS	REFERENCE
Necrotic apical areas of gill filaments excess mucus production	conducted in a laboratory; evaluation performed under a light microscope; exposure to cadmium and preliminary exposures to mercury, silver, zinc, and the chlorinated pesticide methoxychlor were tested.	Gardner, 1975; Gupta and Rajbanshi, 1988
Kidney proximal tubule cell degeneration, increased mucus and necrosis in intestine, gill filament hypertrophy and hyperplasia of respiratory epithelial cells	conducted in a laboratory; evaluation performed under a light microscope; study included hematology.	Gardner and Yevich, 1970; Ghosh and Chakrabarti, 1993; Gill <i>et al.</i> , 1989.
Mercury		
Gill epithelial lifting, epithelial cell hypertrophy, gill aneurysms	conducted in a laboratory; evaluation performed under light and electron microscopes; sections for light and transmission electron microscopy were fixed in 1% OsO ₄ , rinsed, dehydrated in graded concentrations of ethanol and embedded in Epon; preparation for scanning electron microscopy involved the use of Freon TF and the specimens were critical point dried, using liquid CO ₂ .	Karlsson-Norrgren <i>et al.</i> , 1985; also see: Bano and Hasan, 1990; Daoust <i>et al.</i> , 1984; Dey and Bhattacharya, 1989; Khangarot and Somani, 1980; Lock and Van Overbeeke, 1981; Wester, 1991; Wester and Canton, 1992; Harada, 1995.
Gill necrosis and hypertrophy	conducted in a laboratory; evaluation performed under a light microscope; samples were embedded in paraffin, sectioned at 6 µm, and stained with hematoxylin and eosin.	Wobeser, 1975a
Liver cell and connective tissue damage leading to cirrhosis, pyloric caeca and intestinal cell necrosis	conducted in a laboratory; evaluation performed under an electron microscope; samples were embedded in paraffin wax, and 6µm sections were cut and stained with hematoxylin.	Sastry and Gupta, 1978a

Table 2: Histological Effects with Respect to Fish Organs

EXPERIMENTAL CONDITIONS	HISTOPATHOLOGY	COMMENTS	REFERENCE
Gill			
Exposure of rainbow trout to chromate at pH 6.5 for 0, 4, 9 and 11 days of exposure and recovery	Gill epithelial necrosis, fusion, hypertrophy and hyperplasia:	conducted in a laboratory; evaluation performed under light and electron microscopes; recovery experiments enabled to investigate the reversibility of the phenomenon.	Temmink <i>et al.</i> , 1983; also see Skinner, 1982
Windowpane flounder were exposed for 60 days to 5 or 10 µg/L mercury	Focal swellings on the primary lamellae	conducted in a laboratory; evaluation performed under a scanning electron microscope; the ratio of filaments with 'cratered' epithelial cells to total number of filaments examined was calculated for each exposure level.	Pereira, 1988
Dogfish were exposed to 15 ppm zinc for 2 weeks	Proliferation of chloride cells in the primary epithelium	conducted in a laboratory; evaluation performed under an electron microscope; samples were post-fixed in 2% OsO ₄ , dehydrated through ethanol series, stained with uranyl acetate and embedded in Araldite.	Crespo and Sala, 1986
Exposure of bluegills in outdoor pools to sodium arsenite during a 16-week period to weekly treatments of 0.04, 0.4 and 1.2	Gill epithelial lifting, aneurysms liver fatty infiltration and focal necrosis	conducted in a laboratory; evaluation performed under a light microscope; included assessments of the	Gilderhaus, 1966

Technical Evaluation of Histopathology
Re-Issued May 21, 1998

EXPERIMENTAL CONDITIONS	HISTOPATHOLOGY	COMMENTS	REFERENCE
ppm; monthly treatments of 0.4 and 1.2 ppm; yearly treatments of 0.4, 1.2 and 4.0 ppm.		basis of survival, growth, hematocrit measurements, ratio of gonad weight to body weight, and pathological changes in tissues.	
Four month exposure of rainbow trout to 0.5, 1.0 and 1.5 ppm ammonia	Vacuolation and necrosis in gill epithelium	conducted in a laboratory; evaluation performed under a light microscope.	Smith and Piper, 1975
Three week exposure of 0.25- 0.30 µg NH ₃ -N/mL to rainbow trout	Gill aneurysms, epithelial thickening	conducted in a laboratory; evaluation performed under a light microscope; evaluation of both acute and chronic toxicity.	Smart, 1976
Freshwater teleost, <i>H. fossilis</i> (Bloch) was exposed to 8.17 mg/L of copper in static bioassay for 96-hr	Excessive mucus and fusion of secondary lamellae	conducted in a laboratory; evaluation performed under a scanning electron microscope; focus on acute copper toxicity.	Rajbanshi and Gupta, 1988
Rainbow trout exposed to nickel (2.0 and 3.2 mg/L) and chromium (10 and 25 mg/L).	Gill edema (epithelial lifting), fusion of secondary lamellae	conducted in a laboratory; evaluation performed under an electron microscope; relative diffusing capacity was estimated; sections were examined under oil immersion at a magnification of 1413x.	Hughes <i>et al.</i> , 1979
Exposure of rainbow trout to 40 ppm zinc for 75-120 minutes.	Gill epithelial necrosis	conducted in a laboratory; evaluation performed under an electron microscope; following	Matthiessen and Bradfield, 1973

Technical Evaluation of Histopathology
Re-Issued May 21, 1998

EXPERIMENTAL CONDITIONS	HISTOPATHOLOGY	COMMENTS	REFERENCE
		the experiment, recovery period assessed in zinc-free tap water.	
Exposure of rainbow trout to 1.25 mg/L zinc in a semistatic system for 96-hr.	Desquamation of gill epithelium	conducted in a laboratory; evaluation performed under an electron microscope; electron micrographs displayed an increased number of granulocytes in the filamental sinus, and some lifting of the filament epithelium.	Skidmore and Tovell, 1972
96-hr exposure of rainbow trout to 1.25 mg/L zinc.	Fusion of secondary lamellae epithelial lifting)	conducted in a laboratory; evaluation performed under a light microscope; also exposed to dehydroabietic acid (DHAA).	Tuurala and Soivio, 1982
48-hr exposure of the common mummichog to copper at 15 mg/L	Heavy gill-mucus response	conducted in a laboratory; evaluation performed under a light microscope; exposure to cadmium and preliminary exposures to mercury, silver, zinc, and the chlorinated pesticide methoxychlor were tested.	Gardner, 1975
Acute short-term bioassay and long-term bioassay on the brown bullhead, Exposure in aquaria to copper levels of 5 ppm (24 h) and 0.3 ppm (40 days)	Swollen gills, necrotic damage prevalent at 5 ppm	conducted in a laboratory; evaluation performed under a light microscope.	Benedetti <i>et al.</i> , 1989
Exposure of mummichog to 0; 0.9;	Gill necrosis and sloughing of mucosa	conducted in a laboratory;	Voyer <i>et al.</i> , 1975

Technical Evaluation of Histopathology
Re-Issued May 21, 1998

EXPERIMENTAL CONDITIONS	HISTOPATHOLOGY	COMMENTS	REFERENCE
1.9 and 2.9 mg Cd/L at 2.3; 4.1 and 8.5 mg/L DO for 24, 48, 72 and 96-hr.		evaluation performed under a light microscope; seawater-exposed mummichogs were used; differences in the histopathological responses of marine and freshwater-exposed mummichogs.	
Exposure of the common mummichog to 5 mg/L of cadmium for one-year period.	Necrotic apical areas of gill filaments excess mucus production	conducted in a laboratory; evaluation performed under a light microscope; exposure to cadmium and preliminary exposures to mercury, silver, zinc, and the chlorinated pesticide methoxychlor were tested.	Gardner, 1975
Exposure of freshwater zebrafish to 3 and 10 µg/L cadmium for up to 6 weeks. Exposure of rainbow trout to 10 and 100 µg/L cadmium for up to 6 weeks	Gill epithelial lifting, epithelial cell hypertrophy, gill aneurysms	conducted in a laboratory; evaluation performed under light and electron microscopes; sections for light and transmission electron microscopy were fixed in 1% OsO ₄ , rinsed, dehydrated in graded concentrations of ethanol and embedded in Epon; preparation for scanning electron microscopy involved the use of Freon TF and the specimens were critical point dried, using liquid CO ₂ .	Karlsson-Norrgren <i>et al.</i> , 1985

Technical Evaluation of Histopathology
Re-Issued May 21, 1998

EXPERIMENTAL CONDITIONS	HISTOPATHOLOGY	COMMENTS	REFERENCE
Exposure of methyl mercury chloride concentration of 0.01-0.11 mg/L to rainbow fry and fingerlings and mercuric chloride exposure of 0.5, 0.75 and 1.0 mg/L to fingerlings	Gill necrosis, hypertrophy	conducted in a laboratory; evaluation performed under a light microscope; samples were embedded in paraffin, sectioned at 6 µm, and stained with hematoxylin and eosin.	Wobeser, 1975a
Kidney			
General			Mallatt, 1985
Exposure of the common guppy to 1.24 ppm as lead and 1.15 ppm as zinc and 0.5 ppm sodium pentachlorate at 25-27 °C (exposure period not given)	Expanded tubular lumens, debris in lumens and reduced lymphoid tissue in kidney	conducted in a laboratory; evaluation performed under a light microscope; fish were sectioned at 8-12 µm and stained with Delafield's hematoxylin and eosin	Crandall and Goodnight, 1963
Teleost fish <i>Channa punctatus</i> exposed to cadmium concentrations of 0.01, 0.03 and 0.05 ppm for period of 1-51 days	Marked degeneration in glomeruli	conducted in a laboratory; evaluation performed under a light microscope; kidney fixed in Bouin's liquid and sections of 2-3 µm thickness were stained with hematoxylin eosin	Dubale and Shah, 1981
Green sunfish collected from a selenium-rich lake	Proliferative glomerulonephritis and tubular necrosis	field experiment; under an electron microscope; environmentally-exposed fish were collected	Sorensen <i>et al.</i> , 1982
Exposure of the common guppy to 1.24 ppm as lead and 1.15 ppm as zinc and 0.5 ppm sodium pentachlorate at 25-27	Kidney tubule dilation	conducted in a laboratory; evaluation performed under a light microscope; fish were sectioned 8-12 µm	Crandall and Goodnight, 1963

Technical Evaluation of Histopathology
Re-Issued May 21, 1998

EXPERIMENTAL CONDITIONS	HISTOPATHOLOGY	COMMENTS	REFERENCE
°C (exposure period not given)		and stained with Delafield's hematoxylin and eosin	
96-hr bioassay study of mixtures of (0, 1, 2, 3, 8 mg/L) Cu ²⁺ , (0, 3, 6, 12, 36, 60 mg/L) Zn ²⁺ and (0, 1, 10 mg/L) Cd to mummichog at 20‰ salinity and 20°C	Cytoplasmic vacuolation and clumping of nuclear chromatin in proximal tubule cells	conducted in a laboratory; evaluation performed under a light microscope	Eisler and Gardner, 1973
The winter flounder were exposed to medium and high levels of copper (560, 1000 and 3200 µg/L) and low levels of 180 µg/L for two weeks	Kidney necrosis, fatty liver, gill cell vacuolation	conducted in a laboratory; evaluation performed under electron and light microscopes; effects of copper on liver, kidney and gills	Baker, 1969
Histopathology of the kidney of bluegills after 12-hr for 48-hr exposure period to 50 ppm of cadmium	Kidney proximal tubule cell degeneration increased mucus and necrosis in intestine gill filament hypertrophy and hyperplasia of respiratory epithelial cells	conducted in a laboratory; evaluation performed under a light microscope; study included hematology	Gardner and Yevich, 1970
Liver			
Rainbow trout were exposed to cyanide concentrations of 0.00, 0.01, 0.02, or 0.03 mg/L hydrogen cyanide (18 days, 12.5°C)	Degenerative hepatic necrosis in liver	conducted in a laboratory; evaluation performed under light and electron microscopes; included evaluation of growth and metabolic rate; cyanide-exposed fish sustained reduced fat gains	Dixon and Leduc, 1981
Exposure of snake head fish to 6.8 mg/L lead nitrate for 125	Degenerative changes in liver, hepatocellular	conducted in a laboratory; evaluation performed	Sastry and Gupta, 1978b

Technical Evaluation of Histopathology
Re-Issued May 21, 1998

EXPERIMENTAL CONDITIONS	HISTOPATHOLOGY	COMMENTS	REFERENCE
days	dissociation, necrosis, inflammation of portal areas	under a light microscope; enzyme activity was estimated	
Exposure of green sunfish to sodium arsenate concentrations of 0, 30, or 60 ppm and exposure times of one, two, or three weeks at 20°C	Hepatocyte alterations, abundance of intranuclear electron dense particles (EDP)	conducted in a laboratory; under an electron microscope; both living and dead fish were examined	Sorensen, 1976
Four month exposure of rainbow trout to 0.5, 1.0 and 1.5 ppm ammonia	Cytoplasmic degeneration of liver cells	conducted in a laboratory; evaluation performed under a light microscope; tissues were preserved in Bouin's solution; sections were cut at 5 µm; internal organs, brain, gills, and thymus were preserved.	Smith and Piper, 1975
20-day continuous exposure of juvenile gilthead seabream to 1.8; 4.8, 8.2, 13.0 and 15.7 mg/L total ammonia nitrogen at 26°C	Liver cell atrophy, fatty vacuolation. Pathological changes were dose-dependent	conducted in a laboratory; evaluation performed under a light microscope; samples were embedded in paraffin and 6µm thick sections were stained with hematoxylin-eosin and Periodic Acid Schiff.	Wajsbrodt <i>et al.</i> , 1993
Redear sunfish collected from a selenium-rich lake	Centrilobular necrosis and increased phagocytic cells in liver	field experiment; under an electron microscope; environmentally-exposed fish were collected	Sorensen <i>et al.</i> , 1983b
Acute short-term bioassay and long-	Disaggregated patchy areas of	conducted in a laboratory;	Benedetti <i>et al.</i> , 1989

Technical Evaluation of Histopathology
Re-Issued May 21, 1998

EXPERIMENTAL CONDITIONS	HISTOPATHOLOGY	COMMENTS	REFERENCE
term bioassay on the brown bullhead, exposure in aquaria to copper levels of 5 ppm (24 h) and 0.3 ppm (40 days)	degeneration of liver	evaluation performed under a light microscope; tissue copper levels and enzyme levels were determined	
Sub-lethal concentration (0.3 mg/L) of mercuric chloride on a teleost fish, <i>Channa punctatus</i> at 96 hr and 5, 10, 15, 20, and 30 days	Hepatocellular necrosis, regeneration and connective tissue proliferation leading to cirrhosis	conducted in a laboratory; evaluation performed under an electron microscope; samples were embedded in paraffin wax, and 6µm sections were cut and stained with hematoxylin.	Sastry and Gupta, 1978a
Sex Organs			
Female rainbow trout exposed to 0.01 mg/L and 0.02 mg/L hydrogen cyanide for 20 days at 10°C	Decreased maturation of oocytes i.e. reduced vitellogenesis	conducted in a laboratory; evaluation performed under a light microscope	Lesniak and Ruby, 1982
An 18-day exposure of juvenile male rainbow trout to cyanide concentrations of 0.01 and 0.03 mg/L hydrogen cyanide at 12.5°C	Reduced state of sperm development by damaging spermatogonia	conducted in a laboratory; evaluation performed under a light microscope; histological sections from control ovaries were used for establishing the six arbitrary stages of egg development based upon the diameter of the oocyte in combination with cytoplasmic and nuclear features and development of egg membranes and their associated follicular cells	Ruby <i>et al.</i> , 1979

Technical Evaluation of Histopathology
Re-Issued May 21, 1998

EXPERIMENTAL CONDITIONS	HISTOPATHOLOGY	COMMENTS	REFERENCE
Exposure of freshwater tropical perch to 2.0 and 14.0 mg/L concentrations of arsenic (III) oxide for 15 and 30 days	Rupture of testicular lobules	conducted in a laboratory; evaluation performed under a light microscope; the testes was excised, washed and fixed in picromercuro-formol; paraffin sections (6-8 µm) were stained with Heidenham's iron hematoxylin.	Shukla and Pandey, 1984
Impact of 64 mg/L nickel sulphate on the gonads of both sexes of a freshwater tropical perch for two weeks	Reduction of spermatogenesis, tubular degeneration and distension of testicular blood vessels	conducted in a laboratory; evaluation performed under light microscope; gonads were fixed in Bouin's solution; sections 4-6 µm thick were cut, processed and stained with hematoxylin and eosin	Nath and Kumar, 1990
Silver barb exposed to 26 mg/L of cadmium acetate for 96-hr period	Damage of testicular tissue by hemorrhage necrosis	conducted in a laboratory; evaluation performed under a light microscope; the length and weight of the body and testes were recorded; the testes in 4-6 µm sections were fixed in aqueous Bouin's fluid and embedded in paraffin	Pundir and Saxena, 1990
Pancreas			
Redear sunfish collected from a selenium-rich lake	Hypertrophy and hyperplasia of exocrine pancreas	field experiment; under an electron microscope; environmentally-exposed fish were collected	Sorensen <i>et al.</i> , 1983a

EXPERIMENTAL CONDITIONS	HISTOPATHOLOGY	COMMENTS	REFERENCE
Nervous System			
Baatrup, 1991			
Intestine			
Sub-lethal concentration (0.3 mg/L) of mercuric chloride on snake head fish at 96-hr and 5, 10, 15, 20, and 30 days	Pyloric caeca and intestinal cell necrosis	conducted in a laboratory; evaluation performed under an electron microscope; samples were embedded in paraffin wax, and 6µm sections were cut and stained with hematoxylin.	Sastry and Gupta, 1978a
Exposure of bluegills to zinc at 13.6 ppm and iron at 17.1 ppm for 90 days	Necrosis and sloughing off of intestinal epithelium	conducted in a laboratory; evaluation performed under a light microscope; tissues were fixed in Bouin's fluid, prepared with paraffin for sectioning and stained with Harris's hematoxylin and eosin.	Fromm and Schiffman, 1958

Table 3: Histopathological Lesions of Diagnostic Significance With Respect to Pollutants

Organ	Agent	Effect	Reference
petroleum compounds			
Gills	saltwater-soluble crude oil	chloride cell degeneration with hypertrophied perinuclear spaces and smooth endoplasmic reticulum; mitochondria having disorganized cristae and ruptured membranes; formation of autophagosomes, vacuoles, myelinlike bodies, and apical vesicles in epithelial cytoplasm; and reduction in thickness of apical homogeneous epithelial cytoplasm	Hawkes, 1977
	bis(tri-n-butyltin) oxide		Chliamovitch and Kuhn, 1977
	heavy metal salts: CuSO ₄		Baker, 1969
organochlorines			
Liver	DDT	distinct vacuolation of hepatocytes, enlargement and/or vesiculation of rough endoplasmic reticulum, presence of circular arrays of smooth surfaced membranes and myelinlike bodies in hepatocytes cytoplasm, proliferation and "bizarre" whorls of smooth and rough endoplasmic reticulum, loss of glycogen reserves in hepatocytes and presence of cochlear ribosomes, presence of intranuclear and intracytoplasmic electron-dense particles, increased size and numbers of lipofuscin granules, and abnormally enlarged mitochondria	Ramalingam, 1988
	Aroclor 1254		Sivarajah <i>et al.</i> , 1978;
	PCBs		Hawkes, 1980; Hinton <i>et al.</i> , 1978; Klaunig <i>et al.</i> , 1979
petroleum compounds			

Organ	Agent	Effect	Reference
Liver	whole crude oil	distinct vacuolation of hepatocytes, enlargement and/or vesiculation of rough endoplasmic reticulum, presence of circular arrays of smooth surfaced membranes and myelinlike bodies in hepatocytes cytoplasm, proliferation and "bizarre" whorls of smooth and rough endoplasmic reticulum, loss of glycogen reserves in hepatocytes and presence of cochlear ribosomes, presence of intranuclear and intracytoplasmic electron-dense particles, increased size and numbers of lipofuscin granules, and abnormally enlarged mitochondria	Hawkes, 1977
	heavy metal salts: Na ₂ HAsO ₄		Sorensen, 1976
heavy metal salts			
Kidney	CdCl ₂	focal degeneration of first and second proximal tubules with granular, vacuolated cytoplasm containing swollen or dense contracted mitochondria, some having a granular matrix and focal electron densities, epithelium of third proximal tubules having increased numbers of vacuoles, formation of autophagosomes, lipid droplets, nuclei with marginated chromatin, swollen nuclear envelopes and basal membranes contorted into myelinlike figures, distortion of tubular microvilli, and dilation of endoplasmic reticulum	Hawkins <i>et al.</i> , 1980
	HgCl ₂		Trump <i>et al.</i> , 1975; Wassermann and Koepp, 1977
organochlorines			
Pancreas	Dowpon	submicroscopic degeneration of acinar cells of exocrine pancreas	Schulz, 1971
Testes	Arochlor 1254	damage to head region of spermatozoa and loss of serrations in outer membrane	Sirvarajah <i>et al.</i> , 1978

Organ	Agent	Effect	Reference
Ovaries	Arochlor 1254	enlargement and proliferation of smooth endoplasmic reticulum	Sirvarajah <i>et al.</i> , 1978
petroleum compounds			
Skeletal Muscle	whole crude oil	numerous swollen mitochondria with some disruption of internal membranes and cristae and intercellular breakdown of membranes	Cameron and Smith, 1980; Poirier <i>et al.</i> , 1986
Brain	whole crude oil	enlarged and irregularly shaped non-membrane-bound perinuclear and intracellular spaces	Cameron and Smith, 1980
Integument	saltwater-soluble crude oil	increased numbers of mucus glands appearing dilated (with SEM)	Hawkes, 1977
Neurosensory epithelium	saltwater-soluble crude oil	severe damage to receptor organelles in nares epithelium, including degeneration of chemosensory cilia and loss of microridges circumscribing epithelial cells surrounding olfactory organs (observed with SEM)	Hawkes, 1980

* also see Rand and Petrocelli (1985)

Table 4: Nonspecific Histopathologic Lesions With Respect to Pollutants

Organ	Agent	Effects	Reference
organochlorines			
Gills	2,4-D	epithelial hyperplasia with lamellar fusion, epithelial hypertrophy, telangiectasia, edema with epithelial separation from basement membranes, general necrosis, and/or epithelial desquamation	Walsh and Ribelin, 1975
	DDT		Walsh and Ribelin, 1975; Ramalingam, 1988
	diazinon		Anthony <i>et al.</i> , 1986; Banister and Oloffs, 1986
	dichlobenil		Cope, 1966
	dieldrin		Walsh and Ribelin, 1975
	diuron		McCraen <i>et al.</i> , 1969
	endosulfan		Walsh and Ribelin, 1975
	endrin		Eller, 1971
	esteron		Hendricks, 1979
	heptachlor		Andrews <i>et al.</i> , 1966; Wood, E.M., unpublished, in Couch, 1975
	lindane		Bakthavathsalm <i>et al.</i> , 1987
	methoxychlor		Cope, 1966; Lakota <i>et al.</i> , 1978
	mirex		Van Valin <i>et al.</i> , 1968
	Tordon 22K		Hendricks, 1979
Toxaphene	Lowe, 1965; Wood, E.M., unpublished, in Walsh and Ribelin, 1975)		

Organ	Agent	Effects	Reference
petroleum compounds			
Gills	naphthalene	epithelial hyperplasia with lamellar fusion, epithelial hypertrophy, telangiectasia, edema with epithelial separation from basement membranes, general necrosis, and/or epithelial desquamation	DiMichele and Taylor, 1978
	phenol		Fries and Tripp, 1976; Mitrovic <i>et al.</i> , 1968; Reichenbach-Klinke, 1965; Waluga, 1966b)
	salt-soluble crude oil		(Hawkes, 1977)
organophosphates			
Gills	fenthion	epithelial hyperplasia with lamellar fusion, epithelial hypertrophy, telangiectasia, edema with epithelial separation from basement membranes, general necrosis, and/or epithelial desquamation	Jauch, 1979
	malathion		Walsh and Ribelin, 1975; Wood, E.M., unpublished, in Walsh and Ribelin, 1975); Areechon and Plumb, 1990
	methyl parathion		Wood, E.M., unpublished, in Walsh and Ribelin, 1975)
carbamates			
Gills	propoxur	epithelial hyperplasia with lamellar fusion, epithelial hypertrophy, telangiectasia, edema with epithelial separation from basement membranes, general necrosis, and/or epithelial desquamation	Lakota <i>et al.</i> , 1978
	sevin		Armstrong and Millemann, 1974; Walsh and Ribelin, 1975; Ram and

Organ	Agent	Effects	Reference
			Singh, 1988; Rastogi and Kulshrestha, 1990
herbicides			
Gills	acrolein	epithelial hyperplasia with lamellar fusion, epithelial hypertrophy, telangiectasia, edema with epithelial separation from basement membranes, general necrosis, and/or epithelial desquamation	Hendricks, 1979
	amitrole-T		Hendricks, 1979; Poleksic and Karan, 1995
	atrazine		Hendricks, 1979; Walsh and Ribelin, 1975
	dinoseb		Hendricks, 1979; Reimschuessel <i>et al.</i> , 1989
	diquat		Hendricks, 1979
	endosulfan		Riji and Jayabalan, 1993; Schwaiger <i>et al.</i> , 1992
	hydrothol 191		Eller, 1969
	NaTA ₂		Schulz, 1970
	paraquat-CL		Hendricks, 1979
other miscellaneous compounds			
Gill	acid-alkaline pH	epithelial hyperplasia with lamellar fusion, epithelial hypertrophy, telangiectasia, edema with epithelial separation from basement membranes, general necrosis, and/or epithelial desquamation	Daye and Garside, 1976
	bis(tri-n-butyltin)oxide		Chliamovitch and Kuhn, 1977
	DMSO		Benville <i>et al.</i> , 1968
	SLS		Abel and Skidmore, 1975
	"Pesticides"	Ovarian atresia	Sukumar and Karpagaganapathy, 1992
	TFM		Christie and Battle,

Organ	Agent	Effects	Reference
			1963
nitrogenous compounds			
Gills	NH ₃	epithelial hyperplasia with lamellar fusion, epithelial hypertrophy, telangiectasia, edema with epithelial separation from basement membranes, general necrosis, and/or epithelial desquamation	Burkhalter and Kaya, 1977; Smith and Piper, 1975
	NO ₂		Wedemeyer and Yasutake, 1978
heavy metal salts			
Gills	CdCl ₂	epithelial hyperplasia with lamellar fusion, epithelial hypertrophy, telangiectasia, edema with epithelial separation from basement membranes, general necrosis, and/or epithelial desquamation	Gardner and Yevich, 1970
	CuCl ₂ + ZnCl ₂ + CdCl ₂		Eisler and Gardner, 1973
	CuSO ₄		Baker, 1969; Bhatnager and Shrivastava, 1975
	HgCl ₂		Establier et al. 1978b; Wobeser, 1975a
	CH ₃ HgCl ₂		Establier <i>et al.</i> , 1978a; Wobeser, 1975a,b
	NaAsO ₂		Gilderhaus, 1966
chemotherapeutic agents			
Gills	bradophen	epithelial hyperplasia with lamellar fusion, epithelial hypertrophy, telangiectasia, edema with epithelial separation from basement membranes, general necrosis, and/or epithelial desquamation	Reichenbach-Klinke, 1975
	formalin		Smith and Piper, 1972; Wedemeyer and Yasutake, 1974
	malachite green		Reichenbach-Klinke, 1975
	ozone		Wedemeyer <i>et al.</i> ,

Organ	Agent	Effects	Reference
			1979
organochlorines			
Liver	Arochlor 1248	hepatotoxic lesions of fatty infiltration, nuclear or general hypertrophy of hepatocytes, other degenerative changes in parenchyma (cytoplasmic vacuolation, cellular pleomorphism, deposition of bile or ceroid pigments, hydropic degeneration), loss of hepatic glycogen, coagulative hepatocyte necrosis, sinusoidal and vascular congestion, loss of normal muralial architecture, degeneration or necrosis of biliary epithelium, and perivascular or periportal fibrosis	Eller, L.L., unpublished, in Couch, 1975
	Arochlor 1248		Eller, L.L., unpublished, in Couch, 1975
	Arochlor 1254		Couch, 1975; Nestel and Budd, 1975; Sivarajah <i>et al.</i> , 1978
	carbon tetrachloride		Gingerich <i>et al.</i> , 1978; Racicot <i>et al.</i> , 1975
	chlordane		Eller, L.L., unpublished, in Couch, 1975
	2,4-D		Cope <i>et al.</i> , 1970; Walsh and Ribelin, 1975
	DDT		King, 1962; Mathur, 1962; Walsh and Ribelin; 1975
	dichlobenil		Cope <i>et al.</i> , 1969
	dieldrin		Mathur, 1975; Walsh and Ribelin, 1975
	Dowicide G		Crandall and Goodnight, 1963
	endosulfan		Walsh and Ribelin, 1975
	endrin		Grant and Mehrle, 1970; Lowe, 1965;

Organ	Agent	Effects	Reference
			Mount, 1962; Sastry and Sharma, 1978; Wood, E.M. , unpublished, in Couch, 1975
	lindane		Mathur, 1975; Wood, E.M., unpublished, in Walsh and Ribelin, 1975
	methoxychlor		Cope, 1966; Lakota <i>et al.</i> , 1978; Wood, E.M., unpublished, in Walsh and Ribelin, 1975
	tordon 101 and 22k		Hendricks, 1979
	toxaphene		Wood, E.M., unpublished, in Walsh and Ribelin, 1975
petroleum compounds			
Liver	crude oil	hepatotoxic lesions of fatty infiltration, nuclear or general hypertrophy of hepatocytes, other degenerative changes in parenchyma (cytoplasmic vacuolation, cellular pleomorphism, deposition of bile or ceroid pigments, hydropic degeneration), loss of hepatic glycogen, coagulative hepatocyte necrosis, sinusoidal and vascular congestion, loss of normal muralial architecture, degeneration or necrosis of biliary epithelium, and perivascular or periportal fibrosis	McCain <i>et al.</i> , 1978
	naphthalene		DiMichele and Taylor, 1978
organophosphates			
Liver	diazinon	hepatotoxic lesions of fatty infiltration, nuclear or general hypertrophy of hepatocytes, other degenerative changes in parenchyma (cytoplasmic vacuolation, cellular pleomorphism, deposition of bile or ceroid pigments,	Anees, 1976

Organ	Agent	Effects	Reference
		hydropic degeneration), loss of hepatic glycogen, coagulative hepatocyte necrosis, sinusoidal and vascular congestion, loss of normal muralial architecture, degeneration or necrosis of biliary epithelium, and perivascular or periportal fibrosis	
	dimethoate		Anees, 1976
	dylox		Matton and LaHam, 1969
	malathion		Walsh and Ribelin, 1975; Wood, E.M., unpublished, in Walsh and Ribelin, 1975
	methyl parathion		Anees, 1976; Wood, E.M., unpublished, in Walsh and Ribelin, 1975
herbicides			
Liver	acrolein	hepatotoxic lesions of fatty infiltration, nuclear or general hypertrophy of hepatocytes, other degenerative changes in parenchyma (cytoplasmic vacuolation, cellular pleomorphism, deposition of bile or ceroid pigments, hydropic degeneration), loss of hepatic glycogen, coagulative hepatocyte necrosis, sinusoidal and vascular congestion, loss of normal muralial architecture, degeneration or necrosis of biliary epithelium, and perivascular or periportal fibrosis	Hendricks, 1979
	dinoseb		Hendricks, 1979
	diquat		Hendricks, 1979
	paraquat-CL		Hendricks, 1979
other miscellaneous compounds			
Liver	bis(tri-n-butyltin) oxide	hepatotoxic lesions of fatty infiltration, nuclear or general hypertrophy of hepatocytes, other degenerative changes in parenchyma (cytoplasmic vacuolation, cellular pleomorphism,	Chliamovitch and Kuhn, 1977

Organ	Agent	Effects	Reference
		deposition of bile or ceroid pigments, hydropic degeneration), loss of hepatic glycogen, coagulative hepatocyte necrosis, sinusoidal and vascular congestion, loss of normal muralial architecture, degeneration or necrosis of biliary epithelium, and perivascular or periportal fibrosis	
	DMSO		Benville <i>et al.</i> , 1968
	TFM		Christie and Battle, 1963
heavy metal salts			
Liver	CdCl ₂	hepatotoxic lesions of fatty infiltration, nuclear or general hypertrophy of hepatocytes, other degenerative changes in parenchyma (cytoplasmic vacuolation, cellular pleomorphism, deposition of bile or ceroid pigments, hydropic degeneration), loss of hepatic glycogen, coagulative hepatocyte necrosis, sinusoidal and vascular congestion, loss of normal muralial architecture, degeneration or necrosis of biliary epithelium, and perivascular or periportal fibrosis	Gutierrez <i>et al.</i> , 1978; Tafanelli and Summerfelt, 1975
	CuCl ₂		Gardner and LaRoche, 1973
	CuSO ₄		Baker, 1969
	PbNO ₃		Sastry and Gupta, 1978b
	HgCl ₂		Establier <i>et al.</i> , 1978a,b; Gutierrez <i>et al.</i> , 1978; Sastry and Gupta, 1978a
	CH ₃ HgCl ₂		Establier <i>et al.</i> , 1978a; Kendall, 1977
	NaAsO ₂		Gilderhaus, 1966
chemotherapeutic agents			
Liver	CuSO ₄	hepatotoxic lesions of fatty infiltration, nuclear or general hypertrophy of	Reichenbach-Klinke, 1975

Organ	Agent	Effects	Reference
		hepatocytes, other degenerative changes in parenchyma (cytoplasmic vacuolation, cellular pleomorphism, deposition of bile or ceroid pigments, hydropic degeneration), loss of hepatic glycogen, coagulative hepatocyte necrosis, sinusoidal and vascular congestion, loss of normal muralial architecture, degeneration or necrosis of biliary epithelium, and perivascular or periportal fibrosis.	
	sulfamethazine		Wood <i>et al.</i> , 1957
	thiabendazole		Reichenbach-Klinke, 1975
organochlorines			
Kidney	Aroclor 1254	nephrotoxic lesions, including degenerative changes in tubular epithelium (cytoplasmic vacuolation, hydropic degeneration, hyperchromatic nuclei), dilation of tubular lumina, proteinaceous or cellular casts within tubular lumina, tubular necrosis and/or epithelial desquamation, necrosis of interstitial hematopoietic tissues, and excessive development of melanomacrophage centers	Nestel and Budd, 1975
	DDT		King, 1962; Mathur, 1962
	endrin		Mount and Putnicki, 1966; Wood, E.M., unpublished, in Couch, 1975)
	lindane		Wood, E.M., unpublished, in Walsh and Ribelin, 1975
petroleum compounds			
Kidney	napthalene	nephrotoxic lesions, including degenerative changes in tubular epithelium (cytoplasmic vacuolation, hydropic degeneration, hyperchromatic nuclei), dilation of	DiMichele and Taylor, 1978

Organ	Agent	Effects	Reference
	phenol	tubular lumina, proteinaceous or cellular casts within tubular lumina, tubular necrosis and/or epithelial desquamation, necrosis of interstitial hematopoietic tissues, and excessive development of melanomacrophage centers	Waluga, 1966a
organophosphates			
Kidney	diazinon	nephrotoxic lesions, including degenerative changes in tubular epithelium (cytoplasmic vacuolation, hydropic degeneration, hyperchromatic nuclei), dilation of tubular lumina, proteinaceous or cellular casts within tubular lumina, tubular necrosis and/or epithelial desquamation, necrosis of interstitial hematopoietic tissues, and excessive development of melanomacrophage centers	Anees, 1976
	dimethoate		Anees, 1976
	methyl parathion		Anees, 1976; Wood, E.M., unpublished, in Walsh and Ribelin, 1975
herbicides			
Kidney	acrolein	nephrotoxic lesions, including degenerative changes in tubular epithelium (cytoplasmic vacuolation, hydropic degeneration, hyperchromatic nuclei), dilation of tubular lumina, proteinaceous or cellular casts within tubular lumina, tubular necrosis and/or epithelial desquamation, necrosis of interstitial hematopoietic tissues, and excessive development of melanomacrophage centers	Hendricks, 1979
	amitrole-T		Hendricks, 1979
	dinoseb		Hendricks, 1979
	diquat		Hendricks, 1979

Organ	Agent	Effects	Reference
	paraquat-CL		Hendricks, 1979
other miscellaneous compounds			
Kidney	DMSO	nephrotoxic lesions, including degenerative changes in tubular epithelium (cytoplasmic vacuolation, hydropic degeneration, hyperchromatic nuclei), dilation of tubular lumina, proteinaceous or cellular casts within tubular lumina, tubular necrosis and/or epithelial desquamation, necrosis of interstitial hematopoietic tissues, and excessive development of melanomacrophage centers	Benville <i>et al.</i> , 1968
heavy metal salts			
Kidney	CdCl ₂	nephrotoxic lesions, including degenerative changes in tubular epithelium (cytoplasmic vacuolation, hydropic degeneration, hyperchromatic nuclei), dilation of tubular lumina, proteinaceous or cellular casts within tubular lumina, tubular necrosis and/or epithelial desquamation, necrosis of interstitial hematopoietic tissues, and excessive development of melanomacrophage centers	Gardner and Yevich, 1970; Gutierrez <i>et al.</i> , 1978; Hawkins <i>et al.</i> , 1980; Newman and MacLean, 1974; Tafanelli and Summerfelt, 1975
	mixture of CdCl ₂ , CuCl ₂ , and ZnCl ₂		Eisler and Gardner, 1973
	CuSO ₄		Baker, 1969; Bhatnager and Shrivastava, 1975
	HgCl ₂		Establier <i>et al.</i> 1978b; Trump <i>et al.</i> 1975
	CH ₃ HgCl ₂		Establier <i>et al.</i> 1978a; Wobeser, 1975b
chemotherapeutic agents			
Kidney	CuSO ₄	nephrotoxic lesions, including degenerative changes in tubular epithelium (cytoplasmic vacuolation,	Reichenbach-Klinke, 1975

Organ	Agent	Effects	Reference
		hydropic degeneration, hyperchromatic nuclei), dilation of tubular lumina, proteinaceous or cellular casts within tubular lumina, tubular necrosis and/or epithelial desquamation, necrosis of interstitial hematopoietic tissues, and excessive development of melanomacrophage centers	
	emtrysidiana		Reichenbach-Klinke, 1975
	formalin		Smith and Piper, 1975
	kanamycin		McBride <i>et al.</i> , 1975
	malachite green		Reichenbach-Klinke, 1975
	sulfamethazine		Wood <i>et al.</i> , 1957
	sulfonamides		Reichenbach-Klinke, 1975
organochlorines			
Intestine	miscellaneous PCBs	Toxic lesions most commonly reported in the intestine (and occasionally pyloric caecae) include hyperemia; degenerative changes in tips of villi; loss of structural integrity of mucosal folds; degeneration of mucosal epithelium (hypertrophy, vacuolation, hyperchromasia) and/or various smooth muscle layers; necrosis and/or desquamation of mucosal epithelium; cellular debris and excessive mucus in gut lumen; increased numbers of mucus goblet cells; vacuolation or necrosis of submucosa; degenerative changes or necrosis of submucosal vasculature; inflammatory infiltration of submucosa and/or lamina propria.	Hawkes <i>et al.</i> , 1980
	carbon tetrachloride		Gingerich <i>et al.</i> , 1978
	2,4-D		Walsh and Ribelin, 1975

Organ	Agent	Effects	Reference
	DDT		Janicki and Kinter, 1971; King, 1962; Mathur, 1962; Walsh and Ribelin, 1975
	dieldrin		Walsh and Ribelin, 1975
	endosulfan		Walsh and Ribelin, 1975
petroleum compounds			
Intestine	PCBs	Toxic lesions most commonly reported in the intestine (and occasionally pyloric caecae) include hyperemia; degenerative changes in tips of villi; loss of structural integrity of mucosal folds; degeneration of mucosal epithelium (hypertrophy, vacuolation, hyperchromasia) and/or various smooth muscle layers; necrosis and/or desquamation of mucosal epithelium; cellular debris and excessive mucus in gut lumen; increased numbers of mucus goblet cells; vacuolation or necrosis of submucosa; degenerative changes or necrosis of submucosal vasculature; inflammatory infiltration of submucosa and/or lamina propria	Hawkes <i>et al.</i> , 1980
	naphthalene		DiMichele and Taylor, 1978
	phenol		Fries and Tripp, 1976
organophosphates			
Intestine	diazinon	Toxic lesions most commonly reported in the intestine (and occasionally pyloric caecae) include hyperemia; degenerative changes in tips of villi; loss of structural integrity of mucosal folds; degeneration of mucosal epithelium (hypertrophy, vacuolation, hyperchromasia) and/or various smooth muscle layers; necrosis and/or desquamation of mucosal epithelium; cellular debris	Anees, 1976

Organ	Agent	Effects	Reference
		and excessive mucus in gut lumen; increased numbers of mucus goblet cells; vacuolation or necrosis of submucosa; degenerative changes or necrosis of submucosal vasculature; inflammatory infiltration of submucosa and/or lamina propria	
	dimethoate		Anees, 1976
	malathion		Walsh and Ribelin, 1975
	methyl parathion		Anees, 1976
miscellaneous herbicides			
Intestine	atrazine	Toxic lesions most commonly reported in the intestine (and occasionally pyloric caecae) include hyperemia; degenerative changes in tips of villi; loss of structural integrity of mucosal folds; degeneration of mucosal epithelium (hypertrophy, vacuolation, hyperchromasia) and/or various smooth muscle layers; necrosis and/or desquamation of mucosal epithelium; cellular debris and excessive mucus in gut lumen; increased numbers of mucous goblet cells; vacuolation or necrosis of submucosa; degenerative changes or necrosis of submucosal vasculature; inflammatory infiltration of submucosa and/or lamina propria	Walsh and Ribelin, 1975
nitrogenous compounds			
Intestine	NH ₃	Toxic lesions most commonly reported in the intestine (and occasionally pyloric caecae) include hyperemia; degenerative changes in tips of villi; loss of structural integrity of mucosal folds; degeneration of mucosal epithelium (hypertrophy, vacuolation, hyperchromasia) and/or various smooth muscle layers; necrosis and/or desquamation of mucosal epithelium; cellular debris and excessive mucus in gut lumen;	Smith and Piper, 1975

Organ	Agent	Effects	Reference
		increased numbers of mucus goblet cells; vacuolation or necrosis of submucosa; degenerative changes or necrosis of submucosal vasculature; inflammatory infiltration of submucosa and/or lamina propria	
heavy metal salts			
Intestine	CdCl ₂	Toxic lesions most commonly reported in the intestine (and occasionally pyloric caecae) include hyperemia; degenerative changes in tips of villi; loss of structural integrity of mucosal folds; degeneration of mucosal epithelium (hypertrophy, vacuolation, hyperchromasia) and/or various smooth muscle layers; necrosis and/or desquamation of mucosal epithelium; cellular debris and excessive mucus in gut lumen; increased numbers of mucus goblet cells; vacuolation or necrosis of submucosa; degenerative changes or necrosis of submucosal vasculature; inflammatory infiltration of submucosa and/or lamina propria	Gardner and Yevich, 1970; Gutierrez <i>et al.</i> , 1978; Newman and MacLean, 1974
	HgCl ₂		Establier <i>et al.</i> , 1978a,b; Gutierrez <i>et al.</i> , 1978; Sastry and Gupta, 1978a
	CH ₃ HgCl ₂		Establier <i>et al.</i> , 1978a
	PbNO ₃		Sastry and Gupta, 1978b
organochlorines			
Spleen	Aroclor 1254	Atrophy, mottled or blanched in color, hypocellularity (reduction in red and white pulp), fibroplasia, and subcapsular necrosis of blood cells.	Nestel and Budd, 1975
	carbon tetrachloride		Gingerich <i>et al.</i> , 1978
	2,4-D		Walsh and Ribelin, 1975

Organ	Agent	Effects	Reference
	DDT		King, 1962; Walsh and Ribelin, 1975
	dieldrin		Walsh and Ribelin, 1975
	endosulfan		Walsh and Ribelin, 1975
organophosphates			
Spleen	malathion	Atrophy, mottled or blanched in color, hypocellularity (reduction in red and white pulp), fibroplasia, and subcapsular necrosis of blood cells.	Walsh and Ribelin, 1975
carbamates			
Spleen	sevin	Atrophy, mottled or blanched in color, hypocellularity (reduction in red and white pulp), fibroplasia, and subcapsular necrosis of blood cells.	Walsh and Ribelin, 1975
miscellaneous herbicides			
Spleen	atrazine	Atrophy, mottled or blanched in color, hypocellularity (reduction in red and white pulp), fibroplasia, and subcapsular necrosis of blood cells.	Walsh and Ribelin, 1975
other miscellaneous compounds			
Spleen	DMSO	Atrophy, mottled or blanched in color, hypocellularity (reduction in red and white pulp), fibroplasia, and subcapsular necrosis of blood cells.	Benville <i>et al.</i> , 1968
nitrogenous compounds			
Spleen	NH ₃	Atrophy, mottled or blanched in color, hypocellularity (reduction in red and white pulp), fibroplasia, and subcapsular necrosis of blood cells.	Smith and Piper, 1975
chemotherapeutic agents			
Spleen	formalin	Atrophy, mottled or blanched in color, hypocellularity (reduction in red and white pulp), fibroplasia, and subcapsular necrosis of blood cells.	Smith and Piper, 1975
organochlorines			
Pancreas	Dowpon	Islet cell hyperplasia, subcapsular and acinar cell necrosis, vascular congestion, infarction, and edema.	Schulz, 1971
	endrin		Eller, 1971

Organ	Agent	Effects	Reference
petroleum compounds			
Pancreas	naphthalene	Islet cell hyperplasia, subcapsular and acinar cell necrosis, vascular congestion, infarction, and edema.	DiMichele and Taylor, 1978
organophosphates			
Pancreas	abate	Islet cell hyperplasia, subcapsular and acinar cell necrosis, vascular congestion, infarction, and edema.	Eller, L.L., unpublished, in Couch, 1975
other miscellaneous compounds			
Pancreas	DMSO	Islet cell hyperplasia, subcapsular and acinar cell necrosis, vascular congestion, infarction, and edema.	Benville <i>et al.</i> , 1968
chemotherapeutic agents			
Pancreas	sulfamethazine	Islet cell hyperplasia, subcapsular and acinar cell necrosis, vascular congestion, infarction, and edema.	Wood <i>et al.</i> , 1957
organochlorines			
Adrenal Cortex	DDT	Interrenal cell necrosis, cellular and nucleolar hyperplasia and hypertrophy, nuclear hypertrophy, hyperchromatic cytoplasm, cytoplasmic vacuolation, atrophy of cells with clumping of nucleoplasm, high mitotic index, and prominent sinusoids.	King, 1962
	dieldrin		Walsh and Ribelin, 1975
petroleum compounds			
Adrenal Cortex	naphthalene	Interrenal cell necrosis, cellular and nucleolar hyperplasia and hypertrophy, nuclear hypertrophy, hyperchromatic cytoplasm, cytoplasmic vacuolation, atrophy of cells with clumping of nucleoplasm, high mitotic index, and prominent sinusoids.	DiMichele and Taylor, 1978
other miscellaneous compounds			
Adrenal Cortex	SLS	Interrenal cell necrosis, cellular and nucleolar hyperplasia and hypertrophy, nuclear hypertrophy, hyperchromatic cytoplasm,	Bromage and Fuchs, 1976

Organ	Agent	Effects	Reference
		cytoplasmic vacuolation, atrophy of cells with clumping of nucleoplasm, high mitotic index, and prominent sinusoids.	
nitrogenous compounds			
Adrenal Cortex	landfill leachates	Interrenal cell necrosis, cellular and nucleolar hyperplasia and hypertrophy, nuclear hypertrophy, hyperchromatic cytoplasm, cytoplasmic vacuolation, atrophy of cells with clumping of nucleoplasm, high mitotic index, and prominent sinusoids.	McBride <i>et al.</i> , 1979
heavy metal salts			
Adrenal Cortex	ZnSO ₄	Interrenal cell necrosis, cellular and nucleolar hyperplasia and hypertrophy, nuclear hypertrophy, hyperchromatic cytoplasm, cytoplasmic vacuolation, atrophy of cells with clumping of nucleoplasm, high mitotic index, and prominent sinusoids.	Bromage and Fuchs, 1976
chemotherapeutic agents			
Adrenal Cortex	formalin	Interrenal cell necrosis, cellular and nucleolar hyperplasia and hypertrophy, nuclear hypertrophy, hyperchromatic cytoplasm, cytoplasmic vacuolation, atrophy of cells with clumping of nucleoplasm, high mitotic index, and prominent sinusoids.	Smith and Piper, 1972
organochlorines			
Thyroid Gland	endrin	Reduced follicular height and possible hyperplasia	Grant and Mehrle, 1970
heavy metal salts			
Thyroid Gland	CdCl ₂	Reduced follicular height and possible hyperplasia	Gardner, 1975
organochlorines			
Hepatopancreas	Arochlor 1254	Atrophy, reduction in height of tubular epithelium, tubular dilation, necrosis, and desquamation of tubular	Lowe <i>et al.</i> , 1972

Organ	Agent	Effects	Reference
		epithelium	
	DDT		Lowe <i>et al.</i> , 1971
	toxaphene		Lowe <i>et al.</i> , 1971
petroleum compounds			
Hepatopan-creas	phenol	Atrophy, reduction in height of tubular epithelium, tubular dilation, necrosis, and desquamation of tubular epithelium	Fries and Tripp, 1976
organophosphates			
Hepatopan-creas	methyl parathion	Atrophy, reduction in height of tubular epithelium, tubular dilation, necrosis, and desquamation of tubular epithelium	Lowe <i>et al.</i> , 1971
heavy metal salts			
Hepatopan-creas	CdCl ₂	Atrophy, reduction in height of tubular epithelium, tubular dilation, necrosis, and desquamation of tubular epithelium	Establier <i>et al.</i> , 1978b
organochlorines			
Testes	kuron	Stimulation of spermatogenesis and exhaustion atrophy, development of ova-like cells within follicles, general atrophy and hypospermia (lower mean index of spermatogenic development), necrosis of tubular boundary cells with hemorrhage, vasodilation, and congestion, increased numbers of infiltrating macrophages with phagocytized debris, necrosis of primary germ cells with atrophy of seminiferous tubules, fibrosis, and infiltration of mononuclear inflammatory cells	Wood, E.M., unpublished, in Walsh and Ribelin, 1975
miscellaneous herbicides			
Testes	Hydrothol 191	Stimulation of spermatogenesis and exhaustion atrophy, development of ova-like cells within follicles, general atrophy and hypospermia (lower mean index of spermatogenic development), necrosis of tubular boundary cells with hemorrhage,	Eller, 1969

Organ	Agent	Effects	Reference
		vasodilation, and congestion, increased numbers of infiltrating macrophages with phagocytized debris, necrosis of primary germ cells with atrophy of seminiferous tubules, fibrosis, and infiltration of mononuclear inflammatory cells	
other miscellaneous compounds			
Testes	TEPA	Stimulation of spermatogenesis and exhaustion atrophy, development of ova-like cells within follicles, general atrophy and hypospermia (lower mean index of spermatogenic development), necrosis of tubular boundary cells with hemorrhage, vasodilation, and congestion, increased numbers of infiltrating macrophages with phagocytized debris, necrosis of primary germ cells with atrophy of seminiferous tubules, fibrosis, and infiltration of mononuclear inflammatory cells	Stock and Cope, 1969
heavy metal salts			
Testes	CdCl ₂	Stimulation of spermatogenesis and exhaustion atrophy, development of ova-like cells within follicles, general atrophy and hypospermia (lower mean index of spermatogenic development), necrosis of tubular boundary cells with hemorrhage, vasodilation, and congestion, increased numbers of infiltrating macrophages with phagocytized debris, necrosis of primary germ cells with atrophy of seminiferous tubules, fibrosis, and infiltration of mononuclear inflammatory cells	Sangalang and O'Halloran, 1972; Tafanelli and Summerfelt, 1975
organochlorines			
Ovaries	Arochlor 1254	Hyperplasia of germinal epithelium and involution of some ova, decreased frequency of oocyte maturation, cytoplasmic clumping,	Sivarajah <i>et al.</i> , 1978

Organ	Agent	Effects	Reference
	endrin	and fragmentation and karyolysis of ova	Eller, 1971
heavy metal salts			
Ovaries	CdCl ₂	same effects as above	Tafanelli and Summerfelt, 1975
	NaAsO ₂		Gilderhaus, 1966
miscellaneous herbicides			
Stomach	atrazine	Tunica muscularis with nuclear depolarization and cytoplasmic hyperchromasia, general edema, loss of pepsinogen granules from chief cells, disintegration and pyknosis of glandular epithelium with desquamation of gastric mucosa	Walsh and Ribelin, 1975
heavy metal salts			
Stomach	CuSO ₄	Tunica muscularis with nuclear depolarization and cytoplasmic hyperchromasia, general edema, loss of pepsinogen granules from chief cells, disintegration and pyknosis of glandular epithelium with desquamation of gastric mucosa	Bhatnagar and Shrivastava, 1975
	HgCl ₂		Sastry and Gupta, 1978a
	CH ₃ HgCl ₂		Establier <i>et al.</i> , 1978a
chemotherapeutic agents			
Stomach	sulfamethazine	Tunica muscularis with nuclear depolarization and cytoplasmic hyperchromasia, general edema, loss of pepsinogen granules from chief cells, disintegration and pyknosis of glandular epithelium with desquamation of gastric mucosa	Wood <i>et al.</i> , 1957
miscellaneous herbicides			
Esophagus	acrolein	Vacuolation and nuclear condensation (pyknosis) of mucosal epithelial cells and necrosis of all four tunics	Hendricks, 1979
other miscellaneous factors			

Organ	Agent	Effects	Reference
Esophagus	acid-alkaline pH	Vacuolation and nuclear condensation (pyknosis) of mucosal epithelial cells and necrosis of all four tunics	Daye and Garside, 1976
heavy metal salt			
Rectum	HgCl ₂	Erosion of mucosa at tips of the villi	Sastry and Gupta, 1978a
petroleum compounds			
Heart	whole crude oil	Degeneration of ventricular myocardium, hypotonicity with poor circulation, and hemostasis	Gardner, 1975
heavy metal salts			
Heart	C ₂ H ₆ O ₄ Pb	Degeneration of ventricular myocardium, hypotonicity with poor circulation, and hemostasis	Ozoh, 1979b
organochlorines			
Blood Vessels	2,4-D	Vascular anomalies, periodic acid-Schiff (PAS)-positive globular masses in lumina, endothelial separation from basement membrane, subendothelial myositis, and necrosis of arterial wall	Cope <i>et al.</i> , 1970
petroleum compounds			
Blood Vessels	waste motor oil	Vascular anomalies, periodic acid-Schiff (PAS)-positive globular masses in lumina, endothelial separation from basement membrane, subendothelial myositis, and necrosis of arterial wall	Gardner, 1978
miscellaneous herbicides			
Blood Vessels	hydrothol 191	Vascular anomalies, periodic acid-Schiff (PAS)-positive globular masses in lumina, endothelial separation from basement membrane, subendothelial myositis, and necrosis of arterial wall	Eller, 1969
heavy metal salts			
Blood Vessels	NaAsO ₂	Vascular anomalies, periodic acid-Schiff (PAS)-positive globular masses in lumina, endothelial separation from basement membrane, subendothelial myositis, and necrosis of arterial wall	Gilderhaus, 1966
chemotherapeutic agents			

Organ	Agent	Effects	Reference
Blood Vessels	Sulfamethazine	Vascular anomalies, periodic acid-Schiff (PAS)-positive globular masses in lumina, endothelial separation from basement membrane, subendothelial myositis, and necrosis of arterial wall	Wood <i>et al.</i> , 1957
Organochlorines			
Peripheral Blood	heptachlor	Microcytic, hypochronic, hemolytic anemia with high percentages of abnormal and immature erythrocytes; formation of Heinz and Howell-Jolly bodies; poikilocytosis, anisocytosis, hyperchromasia, anisochromasia, and presence of "smudge" cells among erythrocytes; polycythemia; morphological alterations of erythrocyte nuclei including karyorrhexis; neutrophilia; eosinophilia with deformed nuclei, cytoplasmic vacuolation, and reduction in granular mass; and irregularly shaped thrombocyte nuclei	Andrews <i>et al.</i> , 1966
	chlorinated wastewater		Buckley <i>et al.</i> , 1976
heavy metal salts			
Peripheral Blood	CdCl ₂	Microcytic, hypochronic, hemolytic anemia with high percentages of abnormal and immature erythrocytes; formation of Heinz and Howell-Jolly bodies; poikilocytosis, anisocytosis, hyperchromasia, anisochromasia, and presence of "smudge" cells among erythrocytes; polycythemia; morphological alterations of erythrocyte nuclei including karyorrhexis; neutrophilia; eosinophilia with deformed nuclei, cytoplasmic vacuolation, and reduction in granular mass; and irregularly shaped thrombocyte nuclei.	Gardner and Yevich, 1970; Gardner, 1975; Gutierrez <i>et al.</i> , 1978; Newman and MacLean, 1974
chemotherapeutic agents			
Peripheral	formalin	Microcytic, hypochronic, hemolytic	Smith and Piper,

Organ	Agent	Effects	Reference
Blood		anemia with high percentages of abnormal and immature erythrocytes; formation of Heinz and Howell-Jolly bodies; poikilocytosis, anisocytosis, hyperchromasia, anisochromasia, and presence of "smudge" cells among erythrocytes; polycythemia; morphological alterations of erythrocyte nuclei including karyorrhexis; neutrophilia; eosinophilia with deformed nuclei, cytoplasmic vacuolation, and reduction in granular mass; and irregularly shaped thrombocyte nuclei.	1972
	methylene blue		Reichenbach-Klinke, 1975
	ozone		Wedemeyer <i>et al.</i> , 1979
petroleum compounds			
Skeletal Muscle	naphthalene	Edema of myotomes, degenerative myotomal atrophy, and necrosis.	DiMichele and Taylor, 1978
miscellaneous herbicides			
Skeletal Muscle	atrazine	Edema of myotomes, degenerative myotomal atrophy, and necrosis.	Walsh and Ribelin, 1975
	NaTA ₂		Schulz, 1970
other miscellaneous herbicides			
Skeletal Muscle	TFM	Edema of myotomes, degenerative myotomal atrophy, and necrosis.	Christie and Battle, 1963
organochlorines			
Brain	2,4-D	Hyperemia, hemorrhage, vascular congestion and dilation, infarction, cerebral edema, nuclear pyknosis, rupture and hemorrhage of meninx primitiva, and swelling of myelin sheaths around nerve fibers.	Cope <i>et al.</i> , 1970
	DDT		Walsh and Ribelin, 1975
	dieldrin		Walsh and Ribelin, 1975
	endosulfan		Walsh and Ribelin,

Organ	Agent	Effects	Reference
	methoxychlor		1975 Kennedy <i>et al.</i> , 1970
petroleum compounds			
Brain	naphthalene	Hyperemia, hemorrhage, vascular congestion and dilation, infarction, cerebral edema, nuclear pyknosis, rupture and hemorrhage of meninx primitiva, and swelling of myelin sheaths around nerve fibers.	DiMichele and Taylor, 1978
organophosphates			
Brain	malathion	Hyperemia, hemorrhage, vascular congestion and dilation, infarction, cerebral edema, nuclear pyknosis, rupture and hemorrhage of meninx primitiva, and swelling of myelin sheaths around nerve fibers.	Walsh and Ribelin, 1975
other miscellaneous compounds			
Brain	DMSO	Hyperemia, hemorrhage, vascular congestion and dilation, infarction, cerebral edema, nuclear pyknosis, rupture and hemorrhage of meninx primitiva, and swelling of myelin sheaths around nerve fibers.	Benville <i>et al.</i> , 1968
heavy metal salts			
Brain	$^{109}\text{Cd}^{+2}$	Hyperemia, hemorrhage, vascular congestion and dilation, infarction, cerebral edema, nuclear pyknosis, rupture and hemorrhage of meninx primitiva, and swelling of myelin sheaths around nerve fibers.	Aoki, 1978
	CuCl_2		Gardner and LaRoche, 1973
chemotherapeutic agents			
Brain	neguvon	Hyperemia, hemorrhage, vascular congestion and dilation, infarction, cerebral edema, nuclear pyknosis, rupture and hemorrhage of meninx primitiva, and swelling of myelin sheaths around nerve fibers.	Reichenbach-Klinke, 1975
	masoten		Reichenbach-Klinke, 1975

Organ	Agent	Effects	Reference
heavy metal salts			
Spinal Cord	CuNO ₃	Swelling of lipid substance surrounding large nerve cells and "spirality" (twisting of the cord).	Ozoh, 1979a
chemotherapeutic agents			
Spinal Cord	dipterex	Swelling of lipid substance surrounding large nerve cells and "spirality" (twisting of the cord).	Reichenbach-Klinke, 1975
organochlorines			
Integument	toxaphene	Swelling of lipid substance surrounding large nerve cells and "spirality" (twisting of the cord).	Mayer <i>et al.</i> , 1978
petroleum compounds			
Integument	salt-water-soluble crude oil	Swelling of lipid substance surrounding large nerve cells and "spirality" (twisting of the cord).	Hawkes, 1977
	phenol		Mitrovic <i>et al.</i> , 1968; Reichenbach-Klinke, 1965; Waluga, 1966a
organophosphates			
Integument	malathion	Swelling of lipid substance surrounding large nerve cells and "spirality" (twisting of the cord).	Walsh and Ribelin, 1975
carbamates			
Integument	sevin	Swelling of lipid substance surrounding large nerve cells and "spirality" (twisting of the cord).	Armstrong and Millemann, 1974
miscellaneous herbicides			
Integument	atrazine	Swelling of lipid substance surrounding large nerve cells and "spirality" (twisting of the cord).	Walsh and Ribelin, 1975
other miscellaneous compounds			
Integument	bis(tri-n-butyltin) oxide	Swelling of lipid substance surrounding large nerve cells and "spirality" (twisting of the cord).	Chliamovitch and Kuhn, 1977
	acid-alkaline pH		Daye and Garside, 1976
heavy metal salts			
Integument	CdCl ₂	Swelling of lipid substance	Newman and

Organ	Agent	Effects	Reference
		surrounding large nerve cells and "spirality" (twisting of the cord).	MacLean, 1974
	CuCl ₂ + CdCl ₂ + ZnCl ₂		Eisler and Gardner, 1973
	C ₄ H ₆ O ₄ Pb		Ozoh, 1979b
	PbNO ₃		Ozoh, 1979a
chemotherapeutic agents			
Integument	emtrysidina	Swelling of lipid substance surrounding large nerve cells and "spirality" (twisting of the cord).	Reichenbach-Klinke, 1975
	hexa-ex		Reichenbach-Klinke, 1975
	malachite green		Reichenbach-Klinke, 1975
organochlorines			
Lateral line organs	methoxychlor	Necrosis of sensory and sustentacular epithelium with pyknosis and karyorrhesis; necrosis of cuboidal cells lining canal; infiltration of granular leukocytes in canal lumina, walls and peripheral connective tissues; reduction of goblet cell numbers lining canal; neuromast nuclei with enlarged nucleoli; and loss of nuclei in some cells.	Gardner, 1975
petroleum compounds			
Lateral line organs	naphthalene	Necrosis of sensory and sustentacular epithelium with pyknosis and karyorrhesis; necrosis of cuboidal cells lining canal; infiltration of granular leukocytes in canal lumina, walls and peripheral connective tissues; reduction of goblet cell numbers lining canal; neuromast nuclei with enlarged nucleoli; and loss of nuclei in some cells.	DiMichele and Taylor, 1978
heavy metal salts			
Lateral line organs	CuCl ₂	Necrosis of sensory and sustentacular epithelium with pyknosis and karyorrhesis; necrosis	Gardner and LaRoche, 1973

Organ	Agent	Effects	Reference
		of cuboidal cells lining canal; infiltration of granular leukocytes in canal lumina, walls and peripheral connective tissues; reduction of goblet cell numbers lining canal; neuromast nuclei with enlarged nucleoli; and loss of nuclei in some cells.	
	CuCl ₂ + ZnCl ₂ + CdCl ₂		Eisler and Gardner, 1973
	AgCl		Gardner, 1975
petroleum compounds			
Olfactory organs	whole, saltwater-insoluble, and saltwater soluble crude oil	Hyperplasia and cytoplasmic degeneration of neurosensory and sustentacular epithelium with cystlike formations containing cellular debris and remnants of sensory tissue; necrosis of mucosa with cellular debris in lumina, vasodilation, and congestion in submucosa, vacuolation and pyknosis in cells of lamina propria; epithelial metaplasia with replacement of neurosensory and sustentacular cells by a less differentiated epithelium and appearance of extracellular refractile rods in mucosa; and hypertrophy and hyperplasia of mucous goblet cells in mucosal lining.	Gardner, 1975
	naphthalene		DiMichele and Taylor, 1978
other miscellaneous factors			
Olfactory Organs	acid-alkaline pH	Hyperplasia and cytoplasmic degeneration of neurosensory and sustentacular epithelium with cystlike formations containing cellular debris and remnants of sensory tissue; necrosis of mucosa with cellular debris in lumina, vasodilation, and congestion in submucosa, vacuolation and pyknosis in cells of lamina propria; epithelial metaplasia with replacement of neurosensory	Daye and Garside, 1976

Organ	Agent	Effects	Reference
		and sustentacular cells by a less differentiated epithelium and appearance of extracellular refractile rods in mucosa; and hypertrophy and hyperplasia of mucous goblet cells in mucosal lining.	
heavy metal salts			
Olfactory Organs	CuCl ₂	Hyperplasia and cytoplasmic degeneration of neurosensory and sustentacular epithelium with cystlike formations containing cellular debris and remnants of sensory tissue; necrosis of mucosa with cellular debris in lumina, vasodilation, and congestion in submucosa, vacuolation and pyknosis in cells of lamina propria; epithelial metaplasia with replacement of neurosensory and sustentacular cells by a less differentiated epithelium and appearance of extracellular refractile rods in mucosa; and hypertrophy and hyperplasia of mucous goblet cells in mucosal lining.	Gardner and LaRoche, 1973
	HgCl ₂		Gardner, 1975
	AgCl		Gardner, 1975
petroleum compounds			
Eye	whole crude oil	Enlarged abnormally soft lens; degeneration of lens fibers; other degenerative changes such that boundaries between capsule, lens epithelium, and fibers become indistinct; enlargement of lens capsule; corneal degeneration with necrosis of external squamous epithelium and vacuolation of basal epithelium; desquamation of corneal epithelium preceded by poor differentiation between epithelium and substantia propria; swelling of substantia propria after loss of corneal epithelium; hemorrhage in anterior chamber; hemorrhage in	Hawkes, 1977

Organ	Agent	Effects	Reference
	oil slick	periorbital connective tissues; hemorrhage and leukocyte infiltration of lumbus corneae; anophthalmia, microphthalmia, and exophthalmia.	Payne <i>et al.</i> , 1978
carbamates			
Eye	sevin	Enlarged abnormally soft lens; degeneration of lens fibers; other degenerative changes such that boundaries between capsule, lens epithelium, and fibers become indistinct; enlargement of lens capsule; corneal degeneration with necrosis of external squamous epithelium and vacuolation of basal epithelium; desquamation of corneal epithelium preceded by poor differentiation between epithelium and substantia propria; swelling of substantia propria after loss of corneal epithelium; hemorrhage in anterior chamber; hemorrhage in periorbital connective tissues; hemorrhage and leukocyte infiltration of lumbus corneae; anophthalmia, microphthalmia, and exophthalmia.	Walsh and Ribelin, 1975
miscellaneous herbicides			
Eye	atrazine	Enlarged abnormally soft lens; degeneration of lens fibers; other degenerative changes such that boundaries between capsule, lens epithelium, and fibers become indistinct; enlargement of lens capsule; corneal degeneration with necrosis of external squamous epithelium and vacuolation of basal epithelium; desquamation of corneal epithelium preceded by poor differentiation between epithelium and substantia propria; swelling of substantia propria after loss of corneal epithelium; hemorrhage in anterior chamber; hemorrhage in	Walsh and Ribelin, 1975

Organ	Agent	Effects	Reference
		periorbital connective tissues; hemorrhage and leukocyte infiltration of lumbus corneae; anophthalmia, microphthalmia, and exophthalmia.	
other miscellaneous compounds			
Eye	bis(tri-n-butyltin) oxide	Enlarged abnormally soft lens; degeneration of lens fibers; other degenerative changes such that boundaries between capsule, lens epithelium, and fibers become indistinct; enlargement of lens capsule; corneal degeneration with necrosis of external squamous epithelium and vacuolation of basal epithelium; desquamation of corneal epithelium preceded by poor differentiation between epithelium and substantia propria; swelling of substantia propria after loss of corneal epithelium; hemorrhage in anterior chamber; hemorrhage in periorbital connective tissues; hemorrhage and leukocyte infiltration of lumbus corneae; anophthalmia, microphthalmia, and exophthalmia.	Chliamovitch and Kuhn, 1977
	acid-alkaline pH		Daye and Garside, 1976
heavy metal salts			
Eye	CuCl ₂	Enlarged abnormally soft lens; degeneration of lens fibers; other degenerative changes such that boundaries between capsule, lens epithelium, and fibers become indistinct; enlargement of lens capsule; corneal degeneration with necrosis of external squamous epithelium and vacuolation of basal epithelium; desquamation of corneal epithelium preceded by poor differentiation between epithelium and substantia propria; swelling of substantia propria after loss of corneal epithelium; hemorrhage in	Gardner and LaRoche, 1973

Organ	Agent	Effects	Reference
		anterior chamber; hemorrhage in periorbital connective tissues; hemorrhage and leukocyte infiltration of lumbus corneae; anophthalmia, microphthalmia, and exophthalmia.	
	C ₄ H ₆ O ₄ Pb		Ozoh, 1979b
petroleum compounds			
Pseudo-branch	whole crude oil	Degeneration of secretory cells and hypertrophy of epithelial cells with nuclear swelling and occasional ballooning degeneration.	Gardner, 1975
heavy metal salts			
Pseudo-branch	CH ₃ HgCl ₂	Degeneration of secretory cells and hypertrophy of epithelial cells with nuclear swelling and occasional ballooning degeneration.	Wobeser, 1975b
chemotherapeutic agents			
Pseudo-branch	formalin	Degeneration of secretory cells and hypertrophy of epithelial cells with nuclear swelling and occasional ballooning degeneration.	Smith and Piper, 1972
nitrogenous compounds			
Yolk sac	NH ₃	Developmental retardation with failure to absorb the yolk sac and occurrence of blue sac disease syndrome.	Burkhalter and Kaya, 1977
heavy metal salts			
Yolk sac	PbNO ₃	Developmental retardation with failure to absorb the yolk sac and occurrence of blue sac disease syndrome.	Ozoh, 1979a
organochlorine			
Swim bladder	DDT	Air distension in fry and edema.	Burdick <i>et al.</i> , 1964
miscellaneous herbicides			
Swim bladder	atrazine	Air distension in fry and edema.	Walsh and Ribelin, 1975
organochlorine			
Pituitary Gland	DDD	Degranulation of cells.	Ball and Baker, 1969-1970

Organ	Agent	Effects	Reference
chemotherapeutic agents			
Embryonic Tissues	penicillin G procain	Teratomas up to 15% of the progeny from parent fish.	DeCew, 1972
	dihydrostreptomycin sulfate		DeCew, 1972
	oxytetracycline		DeCew, 1972

* adapted from Rand and Petrocelli (1985)

V. HISTOPATHOLOGY: CRITICAL COMMENTARY

Histopathology is the evaluation of visual pathological changes as seen using a microscope. The majority of literature available documents the histopathology of teleosts, and as such this discussion will be limited to finned fish. There are reports of histological evaluation of a number of other organisms; however, due to the scarcity of these reports and the lack of complete data on reproduction and growth parameters (Kerr and Dickie, 1984), there are inadequate data to include other organisms in this discussion.

Quantifying the exposure of fish to a toxicant in the field is challenging, as it is difficult to assess the bioavailable concentration of the toxicant in question. Many factors affect bioavailability including (but not limited to) nutrition, age, sex, and disease status of the fish; metal concentration, speciation and mixture; and other diseases or stresses such as damaged habitat, total suspended solids and altered ecology (Levin *et al.*, 1989; Hrudey *et al.*, 1996; Klaassen, 1996). Even in the controlled environment of the laboratory, there are factors that make extrapolation into the field more difficult.

The histopathological effects of metals are often tested separately, without evaluating the histopathological effects caused by a mixture of those metals (e.g., Hughes *et al.*, 1979). Although this gives us adequate information for individual chemicals, it does little to evaluate the complex interactions, speciation and adsorption to total suspended solids. These factors all impact the bioavailability of the compound in question in the wild (Hrudey *et al.*, 1996; Klaassen, 1996). Not only are there difficulties in the problems stated above, often the materials presented in the literature have scientific problems associated with them.

The number of specimens used in a study will affect the statistical significance of the results (Gad and Weil, 1998). A relationship between the number of observations and the degree of difference among groups of observations relates directly to the validity of the experiment. Generally, the greater the number of observations the greater the power of the statistical test. Conversely, false negatives (failure to show a positive effect) can also depend upon the prevalence of the finding in question (Lilienfeld and Lilienfeld, 1980). Thus, small samples of low prevalence findings do little to further our knowledge about experimental questions that are asked. There are a number of examples where numbers have been inadequate to achieve an answer to the hypothesis being tested, e.g., Hughes *et al.* (1979).

Dose and response are often inadequately described and evaluated in the literature. This may be partly due to questionable descriptions of a response in some situations, but is more

commonly a problem associated with inadequate dose ranges. Experimental dosing must range from a no effect level to an effect level (NOAEL), otherwise the relationship between dose and response cannot be determined (Klaassen, 1996). Failure to show histopathological changes does not necessarily mean that the compound is not toxic, it just means at the *dose* tested there was no effect observed. For an example of this phenomenon the reader should consult Waite *et al.* (1990).

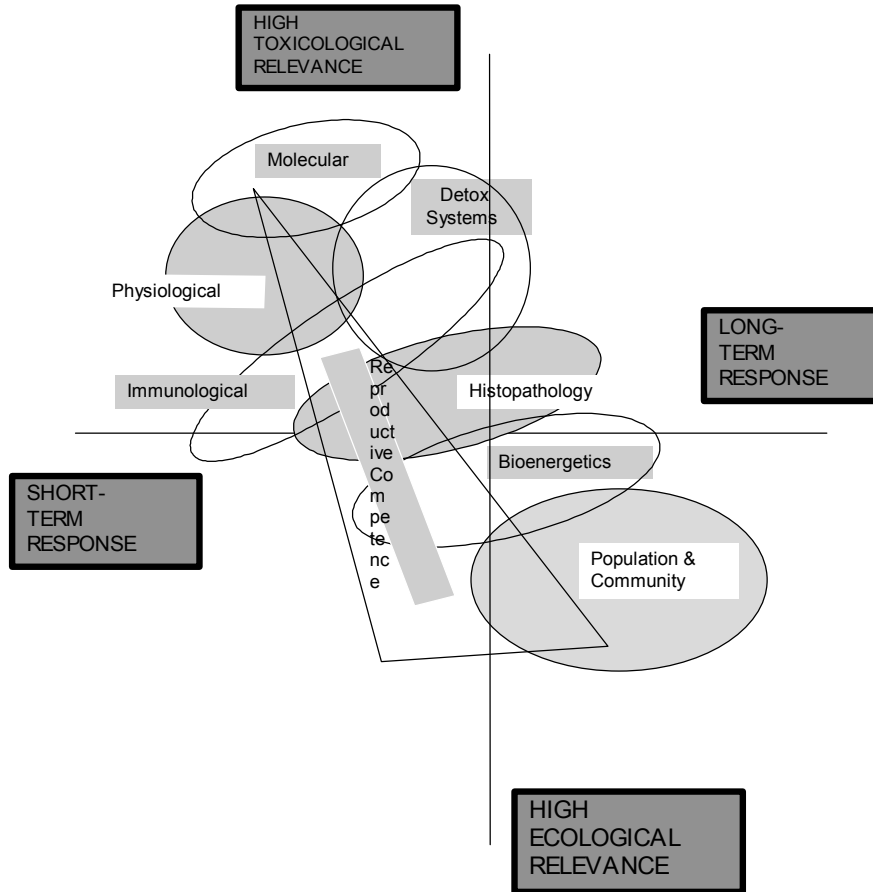
Dose is only one part of the bioavailability and toxicity picture. Exposure is essential for predicting risk and very important to consider when evaluating response, but also *a priori*. Exposure has three main components, all of which may effect the toxicological (and histopathological) outcomes: magnitude (dose), duration (dose × time) and frequency (Σ dose). As most studies choose only one temporal dosing regimen, it is difficult to extrapolate the findings into the field. There have, however, been some attempts to evaluate duration (dose × time), e.g., mercuric chloride (Banerjee and Bhattacharya, 1994).

The literature does have a few citations which report histopathological findings from field-collected animals (McCain *et al.*, 1977; Saltes and Bailey, 1984; Black, 1983; Sorensen *et al.*, 1983a; 1983b; Waite *et al.*, 1990; Myers *et al.*, 1990; Lind *et al.*, 1977; Rousseaux *et al.*, 1995).

McCain *et al.* (1977) collected English sole, *Parophrys vetulus*, and evaluated them for hepatomas. Although attempts were made to relate these findings to pollution, the results were not definitive. Myers *et al.* (1990) continued this work in English sole, *Parophrys vetulus*, but was not able to establish a causal relationship between pollutants and hepatic tumors, although there were significant correlations between histopathology and fluorescent metabolites of aromatic compounds. Similarly, Rousseaux *et al.* (1995) showed excellent correlations between hepatic pathology and EROD levels in field caught lake sturgeon, *Acipenser fulviensis*. Regardless of the relationships, the best overview of how histopathology and other biomarkers/ bioindicators relate has been developed by Adams *et al.* (1989). A stylized copy of this diagram is represented below as **Figure 1**.

In some rare cases, comparative field and laboratory studies have been undertaken (Black, 1983). Correlations between sediment polycyclic hydrocarbons, neoplasms in feral fish, and the induction of neoplasms in bullheads, *Ictalurus nebulosus*, by exposure to extracts of polluted sediment supported his hypothesis that some fish neoplasia may result from exposure to chemicals present in the fish environment.

Figure 1: Levels of biological response in fish to pollutant stress illustrating the continuum of these responses along gradients of response time and toxicological and ecological relevance.



A. Fish Histopathology - Laboratory Approaches

1. Diagnostic Methodology

a) Overview

The process of making a clinical and pathological diagnosis involves scientific, factual information and judgmental thinking, and is therefore not a purely stochastic process (Thomson, 1984; 1988). The need for using judgment lies in the fact that very few diseases have specific visual markers (i.e. are pathognomonic). Therefore, the majority of diagnoses are made by evaluating population biological findings, physical examination findings, and laboratory results of the fish *concurrently*, then selecting a series of possible diagnoses (differential diagnoses) using a weight-of-evidence approach. The final step in making a diagnosis (definitive diagnosis) entails eliminating other diagnoses on the differential diagnoses list through further clinical and laboratory evaluation (Hill and LaVia, 1980).

In cases where a definitive diagnosis cannot be made initially, the progression of the disease adds important clues. Both progression and regression of clinical signs and temporally altered laboratory results can help the clinician be more certain of the diagnosis (Martin *et al.*, 1987). Indeed, waxing and waning of clinical signs is often a primary clinical tool used in the diagnostic process (Ruben and Rousseaux, 1991). Similarly, response to treatment and change in response following removal of a pollutant may confirm a diagnosis.

Unfortunately, clinical and pathological evaluation of individual teleosts over time is not often possible nor practical.

b) Temporal Change

When presented with a fish demonstrating overt clinical signs, the pathologist must rely on the biologist's reporting of past events to assess the development of the disease. In some cases, past time points and progression of the disease may not have been recognized, hence the cause may be missed. For diseases that are well defined with respect to their progression, a prognosis (prediction of future progression of the disease) can be made at this stage (Bucci, 1991). Usually, pathological prognostication is confined to the individual fish. A human example could be the evaluation of a breast lump for malignancy. However, even in an individual's disease there are a number of situations where progression or regression of the disease is not known until follow-up studies are done (Moulton, 1978). When evaluating fish, the baseline study serves the same purpose as the initial biopsy by giving us a "snapshot" view of fish health at that point in time. Further studies can show changes among

“snap-shots.” At present there is a dearth of literature concerning details of histopathological findings in the field with respect to the mining industry.

c) Judgment and Diagnoses

Science operates on principles of deductive, reductionist logic. In a scientific experimental setting, events are broken down into their smallest possible sizes and held constant while a comparison is made between one specific event and specific outcome to determine their relationship. When evaluating fish pathology, multiple temporal-spatial processes are in effect, thus prohibiting the use of the classical reductionist approach in the field. For this reason the pathologist must rely on judgment through weight of evidence to determine the most likely diagnosis. The process of judgment is essential in environmental effects monitoring as data gaps and temporal-spatial fluidity prevent a purely reductionist approach to determining the cause and significance of changes seen.

2. Fish histopathology methodology

The materials that the pathologist needs and how these materials should be preserved and transported follows (Yasutake, 1987). The process of tissue treatment and slide preparation can be found elsewhere in any standard histopathology text (e.g., Roberts, 1989).

a) Sampling

Samples are usually taken by the sponsor, or are sent from the testing laboratory in question. Following exposure to the toxicant and preceding euthanasia, fish should immediately be preserved. If death occurs, the fish should be preserved as soon as possible. If the fish are dead upon collection, the specimens that died most recently should be used. It is essential to remove and "fix" or preserve fish before they die (or as close to death as possible) as the process of autolysis rapidly ensues following death (Thomson, 1984). Autolysis (*auto*-self; *lysis*-destruction) occurs in all living forms following death, and is one of the causes of the unpleasant odor of dead tissue. This self digestion makes pathological evaluation difficult, and often limits its use as it may obscure pathological changes caused by external agents. For this reason tissues should be fixed in 10% buffered (pH 7.0-7.4) formalin (i.e. a solution of 4% formaldehyde gas in a buffered solution)¹. The formaldehyde in the solution "fixes" the tissues by denaturing proteins, stabilizing membranes and preventing the "auto-destruct"

¹ CAUTION: Formalin is corrosive and is an animal cancer-causing agent. For this reason the use of protective clothing and a fume hood, or well ventilated space (not necessary in a boat!) is necessary to maintain occupational health and safety standards.

enzymes from operating (Slauson and Cooper, 1990). As it is the formaldehyde gas that fixes the tissue, it is essential to allow penetration of the formalin. Therefore the preservation method described below should be used.

b) Preservation

All tissues must be fixed for 48 hours prior to submission to a pathology laboratory unless different treatment is specifically requested by the pathologists. For fish that are less than four centimeters long, full immersion just prior to death should be undertaken. It may be valid to chill, anesthetize, or concuss the moribund fish for humane reasons prior to fixation, but the fish to be preserved must *not be frozen*.

Larger fish require necropsy examination (*necros*-death; *opsy*-dissection). In medium sized fish (about 10 cm), opening of the abdomen to allow entrance of the fixative is often all that is necessary. In large fish it will be necessary to remove the organs. In this case it is important to record findings and make sure that the tissue samples are representative of the organ and they are neither too large or too small. It is the formaldehyde gas that fixes the tissue; therefore, tissue should not be thicker than one centimeter and there should always be a *10:1 formalin to tissue ratio*. The technique required when using alternative fixatives should be carefully reviewed prior to sampling. Bouin's fixative, for example, is often reported to be the fixative of choice (e.g., Ram and Sathyanesan, 1986). However, it is not as practical to use in the field because of its poor penetration, one needs to wash the specimen several times in either water or 70% ethanol 24 hours following submersion (failure to do so results in rigid tissues and very poor histological specimens), and its corrosive and staining properties. The picric acid used in Bouin's fixative can also be an explosion hazard. Therefore, this fixative should only be used in a research setting and not in the field. Formalin still remains the most useful general fixative (Johnson and Bergman, 1984).

Tissues are just as easily damaged postmortem as antemortem. For this reason care in handling tissues is necessary. By squeezing the organs, severe structural changes may hinder the pathologist's view of any real effects. Freezing, mishandling of tissue and incorrect fixation can also cause artifacts. These alterations of structure make evaluation of tissues difficult (Thomson, 1984), and may obscure or invalidate pathological findings.

c) Sampling in the Field

Under field conditions, many samples are required for evaluations other than histopathology. Field conditions are often less than optimal for taking, preserving, and storing specimens for biochemistry and histopathology. For this reason, it is necessary to have a detailed plan before capturing and processing the fish. Preparing data collection sheets, pre-labeling

collection containers, and coordinating processors is essential to optimize sample collection and the subsequent tissue analysis. It is important, although not yet mandated in aquatic field studies, to ensure that records are kept and a chain of custody form is used (OECD, 1993). Collection logistics must consider both the importance of proper preservation of material for enzyme analysis and the proper fixation of histological tissue samples as the process of cellular autolysis affects both evaluations.

d) *Submission of Specimens*

Submission of specimens can be done *via* courier provided the following conditions are met:

1. Preservation of the specimen must be maintained;
2. Safety precautions must be taken to protect yourself and others from harm caused by the fixative; and,
3. Compliance with the law regulating transport of hazardous materials (such as formalin) must be maintained.

e) *Preparing the Sample for Shipping*

Fourty-eight hours of fixation should adequately preserve the samples. Following this preservation period, the samples should be prepared for shipping to the pathology laboratory. This will involve a three-tiered container system which will help compliance with sample transport/submission conditions listed above.

First, each fish, or sample of fish, should be placed into a separate sealed bag. Usually milk bags (Whirl-Pak®) are best as Ziploc® and other bags tend to leak under pressure. Once the bagged samples have been labeled, place some absorbent material moistened with formalin in with the sample, and seal the bag.

Next, place the individual bags in a secondary container (this can be another sealed bag). In this secondary container, there should be sufficient absorbent material to absorb all formalin in the package should the primary container fail. Any absorbent material, including paper towels, will be appropriate.

Finally, place the whole package in the tertiary container. Enclose the appropriate chain of custody forms. This container should be substantial and not affected by trauma during transportation. A cooler is an excellent choice. This container must also bear a label clearly listing the contents, the sender, the intended recipient, and the hazards contained in the package.

f) Shipping the Sample

Send the fish samples by courier to the pathology laboratory, or the pathologist. This enables maintenance of the chain of custody for transport.

3. The Process of Evaluation

a) Evaluation of Samples

Upon receipt of the samples, the pathologist opens the samples and records their condition, their date of arrival, and any gross lesions (abnormal findings on the body surface). Next the pathologist or histotechnologist carefully inspects samples and trims sub-samples to fit into histology cassettes for tissue processing. Care is taken to make sure that any gross lesion described by the field collector is placed into a cassette for processing.

b) Processing of Samples

(1) Tissues

Following trimming, all tissues sampled are routinely processed, sectioned at 5 μm , stained with hematoxylin and eosin, and mounted.

Routine processing is a multi-step process that takes approximately 24 hours. It involves dehydrating tissues, putting them into a xylene phase, and impregnating them with paraffin wax under vacuum. Following this process, the tissues are embedded in wax that holds the tissues for sectioning (usually one tissue per "block") and are sectioned on a microtome. These sections are placed on glass slides and stained following attachment of the section to the slide by heating. Following staining, the sections are covered with a coverslip and mounted for evaluation by the pathologist (Cotran *et al.*, 1989). This process requires a histotechnologist to produce optimal sections to obtain a diagnosis. The quality of sections critically impacts the ability of the pathologist to evaluate the tissues. There have been suggestions that plastic embedding be used on a routine basis (Johnson and Bergman, 1984). In our experience, although plastic embedding in compounds such as epon allows thin section preparation (1 μm), the method is neither cost-effective, nor time-effective unless being used as the first step of preparing electron microscopic grids.

Where necessary, special stains are used to highlight specific lesions or causative agents (e.g., pathogenic organisms such as bacteria). Parasites are identified wherever possible. For detailed parasitic examination, evaluation of submitted whole parasites is necessary. Future recall from the archives for comparison can be made using a block coding system (OECD, 1993).

(2) Whole Specimens

Small fish, less than 4 cm long, can be placed in cassettes and processed as above. This preparation technique provides a section of multiple organs *in situ* for evaluation.

Preparation of specimens for teratological evaluation can be done following division of the fry into parts (usually 2/3 skeletal and 1/3 visceral). Specimens intended for skeletal evaluation should be well fixed in 70% alcohol (usually ethanol). Those specimens to be evaluated for visceral changes should be fixed in Bouin's fixative for at least 2 weeks to allow decalcification of the skeleton. Once a tissue is fixed, a modified Wilson freehand sectioning technique can be applied (Wilson and Fraser, 1977) and the cross-sections can then be evaluated and compared.

Skeletal evaluation is slightly more time consuming. The fixed specimens usually do not have to be skinned, eviscerated and de-fatted as with mammalian embryology. However, dense pigmentation of the skin may lead to difficult skeletal evaluation. The staining and clearing method relies on Alcian Blue staining of the cartilage, Alizarin Red staining of the bone, potassium hydroxide maceration of the soft tissues, and clearing with glycerine (Rousseaux, 1985).

c) Reading the Slides

The duty pathologist reads the slides looking for abnormal structural changes (morphology). When no abnormal morphology is seen for a tissue the term No Visible Lesion (NVL) is stated to show that the organ was evaluated but no abnormal findings were seen. Morphological abnormalities that are recorded include findings that are related to exposure and those that are not. It does not matter whether the biologically significant findings are related to exposure or not as all findings are usually reported for each organ. Morphological alterations in the skeleton or viscera of fry can be classified into major, minor, and variant abnormalities (Rousseaux and Blakley, 1991). The relationship of specific malformations to toxicant exposure is still in its infancy, and as such must be done on a case-by-case comparative basis.

4. Training

The training of a diagnostic pathologist takes many years. The first requirement is an individual with a basic medical or paramedical training (such as a medical or veterinary degree). Second, the individual takes an intensive apprenticeship training to become an expert in the biology of organ damage caused by normal and abnormal degenerative, inflammatory and neoplastic (cancerous) processes (Cotran *et al.*, 1989). Finally, the pathologist should obtain the proper certification or qualifications. Certification includes:

Diplomate of the American College of Veterinary Pathologists (ACVP), Member or Fellow of the Royal College of Pathologists (MRCPath, FRCpath, FRCP (C), etc.), MVSc, PhD, DVSc, or other post graduate diplomas given by institutions with pathology departments.

There is some misunderstanding as to who can “do histopathology.” Individuals that have graduated through a university program which includes histology may have excellent abilities to evaluate individual cellular and organ morphology, and as such may be able to evaluate known tissue damage caused by specific toxicants (Johnson and Bergman, 1984). This adds to our understanding of pathology through the experimental wing of the discipline, but these individuals cannot give the same overview of fish health as a person who has gone through basic medical training and the pathology apprenticeship to enable them to act as pathologists. For this reason, the combined expertise of both individuals can improve the outcome of morphological evaluation of fish.

5. Quality Assurance

Quality assurance in histopathological studies occurs at two levels: slide preparation and pathological interpretation. Slide preparation must employ strict verification protocols to ensure that the tissue examined by the pathologist is in fact the tissue collected in the field. Each laboratory has different methods of addressing quality assurance. Because of the subjectivity of histopathology, serious consideration should be given to a peer review of pathological evaluations by a second qualified examiner (Hildebrandt, 1991).

6. Dose-Response Relationships

Dose-response relationships are necessary to predict *a priori* the likely outcome of exposure to a specific contaminant. The concentration at which specific pathology occurs is a useful threshold in determining the No Observable Adverse Effect Concentration (NOAEC) or No Observable Effect Concentration (NOEC) (Klaassen, 1996). There are some issues that do need consideration when determining the dose-response relationship.

a) Toxicokinetics

Toxicokinetics, or what happens to the contaminant inside the fish, has a significant effect on the dose-response, as it is the molecular dose that reaches the target site that is important in a toxic response (Jeffrey, 1991). Toxicokinetics are equivalent to pharmacokinetics for drugs and have four components: absorption, distribution, biotransformation and elimination (ADME). The bioavailability of the compound is the single most important factor in determining toxicity (Hrudey *et al.*, 1996).

(1) Absorption

Compounds can be absorbed by fish at numerous sites (Lock, 1975). Uptake of chemicals from the water column occurs primarily through the gill membranes and epithelial membranes, while sediment-bound compounds are usually absorbed from dietary sources. Absorption depends on many parameters, including the chemical properties of the compound (such as partition coefficient, solubility, speciation, etc.), the properties of the water matrix (pH, hardness, alkalinity, temperature, etc.), and the biological properties of the fish (life-cycle stage, species, and other variables which might affect membrane characteristics, exposure-related behavior, and metabolic rate (if uptake is active).

(2) Distribution

Distribution of the compound within the fish is determined by the properties of the compound and the fish tissues. The contaminant load of the fish also can affect distribution through interaction with the new contaminant, release of another bound contaminant and prevention of biotransformation and elimination of another contaminant (Klaassen, 1996). The species and age of the fish can affect distribution through altered organ volume. Age and species can also affect biotransformation and metabolism (Klaassen, 1996). Most importantly the nutritional status of the individual can affect distribution through altered fat depots. This fat is particularly important for fat soluble contaminants (Branchaud *et al.*, 1995).

(3) Metabolism/Biotransformation

Biotransformation, or metabolism, of a compound is dependent upon the physicochemical properties of the compound in question and the biology of the fish. The compound's characteristics determine whether biotransformation will be rapid or prolonged. The species of fish, age, sex, concurrent disease, food availability, nutritional status and contaminant load all affect the individual's ability to enzymically alter the parent compound. The rate of biotransformation may have a beneficial or adverse effect for the fish depending on whether the parent compound or the metabolite is the putative toxicant (Jeffrey, 1991).

(4) Excretion/Elimination

Excretion and elimination is mainly a function of the species in question. However, the chemical properties of the contaminant may result in trapping of the compound within the body (Klaassen, 1996). The metabolic rate, gastrointestinal motility, age, sex and nutritional status all affect excretion. In addition, fish with diseases affecting the kidney may show reduced elimination (Pritchard and Renfro, 1984).

b) Responses

As with all biological endpoints, there is a normal variation in expression of endpoints approximating a gaussian distribution. The same holds true for toxicity and lethality in animals and fish (Arnold *et al.*, 1990). For evaluating the average concentration that has an effect, a cumulative distribution is usually developed to enable establishment of a median toxic or lethal concentration (Adams *et al.*, 1996; Klaassen, 1996). To define this concentration, a probit analysis or tabular evaluation can be done provided the exposures are geometrically related (Gad and Weill, 1988; Krewski and Franklin, 1991).

When fish are exposed to metals and other toxic compounds in increasing doses, the following progression of events occurs with increasing concentrations:

- measurable exposure (e.g., concentration of the suspect toxicant in the tissues);
 - ⇒ physiological adaptation (e.g., increased liver enzymes such as EROD);
 - ⇒ morphological adaptation (e.g., hypertrophy of cells);
 - ⇒ physiological maladaptation - toxicity (e.g., increased respiratory rate/coughing)
 - ⇒ pathological changes (e.g., tissue necrosis and other morphological changes)
 - ⇒ death

From this progression, it can be seen that pathological changes known to be associated with specific compounds give proof of toxicity, especially when compared with other enzymatic changes, which give an indication of response to exposure which may or may not have implications for fish health (such as EROD).

Pathological changes do not occur instantaneously. Firstly, the compound must become bioavailable to the target tissues (Hrudey *et al.*, 1996). Secondly, the compound must interact with cells on a molecular level to either form malone dialdehyde in cell membranes, interact with DNA, or damage the cell's organelles (Slauson and Cooper, 1990). Thirdly, the molecular changes must result in visible ultrastructural changes, such as mitochondrial swelling (Cheville, 1983). Fourthly, cellular changes visible to the light microscope must develop, such as apoptosis, necrosis and inflammation and possibly neoplasia (Cotran *et al.*, 1989). Finally, but by no means always, the amount of cellular change may become visible under a dissecting microscope or to the naked eye (Thomson, 1984). In the case of teratogenesis, it is the final step that is observed under the microscope in all but the most sophisticated experimental settings (Wilson and Fraser, 1977).

The time taken to develop histopathological changes depends on the tissue in question (Thomson, 1988). Tissues such as the brain may show subtle tinctorial changes within the hour, whereas bone may take days to develop cellular changes fully (Hill and LaVia, 1980).

The response to injury also takes time. The inflammatory response to necrotic tissue begins within the first 24 hours, but it takes a number of days before organization (fibrosis) begins. Fish show six types of inflammation including serous, fibrinous, purulent, hemorrhagic, catarrhal, and lymphocytic or granulomatous inflammation (Meyers and Hendricks, 1985), and it can take months for the final stage of scarring to be completed (Hill and LaVia, 1980; Ashley, 1975; Thomson, 1984; Ferguson, 1989; Hinton and Lauren, 1990a). In the case of neoplasia, it is often necessary to receive continual exposure to compounds for the majority of the fish's life before tumors develop (Hendricks, 1982; Maronpot, 1991). For this reason sudden death by intoxication may not result in florid lesions (Ruben and Rousseaux, 1991).

Temporality also can cause difficulties in extrapolating changes found in the laboratory into the field. Pathological changes following acute exposure do not often correlate well with the pathology seen following chronic exposure (Rousseaux, 1985). Chronic effects are more a function of the magnitude, frequency and duration of exposure (Hrudey *et al.*, 1996; Brecher, 1997). To be able to use results of histopathologic experiments in the field, similar exposure and concentration regimens must be compared.

c) Mixtures

Chemical contaminants rarely occur as a single entity. In the case of the dose response curve, the median toxic dose and the median lethal dose may be significantly altered in an additive, subtractive, potentiative, or synergistic manner (Jeffrey, 1991; Klaassen, 1996). These factors make it even more difficult to extrapolate laboratory dose-response findings to those seen in the field (Villeneuve *et al.*, 1994). Finally, other impacts on fish, such as suspended materials may increase toxicity by abrading the gills.

7. Predictive Value

a) Contaminant

Nothing is more predictive than pathognomonic lesions. For example, the cross-section of a parasite with surrounding inflammation in a kidney is the equivalent of the "smoking gun" for the cause of the focal nephritis. In contrast, contaminants that cause physiological alterations resulting in death or have non-specific effects (e.g., hepatocellular lipidosis) are not identifiable as the cause of morphological alterations or death by histopathological examination unless this evaluation is one of a suite of tests (Hill and LaVia, 1980; Thomson, 1984; 1988; Dodd, 1991; Villeneuve *et al.*, 1994). In such cases each test, including pathological examination, does not define the contaminant; however, by evaluating all tests together, the classification of causative agents may become clearer (Cotran *et al.*, 1989).

b) Outcome

Depending on the situation, the predictive value of histopathology varies from good to excellent in determining the health outcome of the individual. Specific endpoints can be evaluated, such as reproductive organ morphology, giving excellent data for extrapolation to reproductive effects (Johnson and Bergman, 1984). Disease status may also give information for both the individual and the population (Kerr and Dickie, 1984). However, lesions such as acute gill necrosis may account for the sudden death of the individual, but fail to predict sub-lethal effects (Lock, 1975; Adam and Schwevers, 1993).

B. Fish Histopathology - Field Approaches

There is a dearth of literature concerning the critical evaluation of fish histopathology in environmental effects monitoring for the mining industry. However, recent publications have addressed histopathology as part of fish health evaluation and site comparisons particularly in the pulp and paper industry (Adams *et al.*, 1996; Teh *et al.*, 1997). There has been an environmental specimen bank created for comparisons and references that also gives valuable background data (Colgrove, 1966; Eurell and Haensly, 1982; Gardner and Yevich, 1969; Wise *et al.*, 1993; Wise and Koster, 1995).

The use of histopathology in environmental monitoring is best found in the pulp and paper and textile industries, where a variety of reports show temporal and positional differences in disease processes (Bengtsson, 1975; Bengtsson *et al.*, 1988a; Bengtsson *et al.*, 1988b; Coulliard *et al.*, 1988; Coulliard *et al.*, 1995; Davis, 1976; Dethlefsen, 1980; Fujiya, 1961; Gangnon *et al.*, 1994; Hodson *et al.*, 1992; Hoffer and Bucher, 1990; Johnson *et al.*, 1988; Kloepper *et al.*, 1994; Lehtinen and Oikari, 1980; Lehtinen *et al.*, 1984; Lindesjöo and Thulin, 1987; 1990; 1992; Lindesjöo *et al.*, 1994; Murugesan, 1988; Murugesan *et al.*, 1989; Murugesan and Haiffa, 1992; Thulin, 1987; 1990; 1992; 1994; Mitz and Giesy, 1985; Owens, 1991; Servos *et al.*, 1992; Sharples *et al.*, 1994; Thulin *et al.*, 1988). Other references are available for gross and microscopic pathology in fish associated with pollutants excepting those associated with the mining industry (Hinton *et al.*, 1973; Johnson and Bergman, 1984; Basch *et al.*, 1971; Becker *et al.*, 1987; Bodammer and Murchenalo, 1990; Brown *et al.*, 1979; Brusle, 1991; Bucher and Hoffer, 1993; Chevalier and Moreau, 1985; Chouhan and Pandey, 1987; De-peyster *et al.*, 1993; Cross, 1985; Grizzle *et al.*, 1988; Gronlund *et al.*, 1991; Gardner and Yevich, 1988; Haensly *et al.*, 1982; Haley *et al.*, 1995; Hall *et al.*, 1992; D'Agpstomo *et al.*, 1992; Diaz-Yubero, 1980; Doudoroff and Katz, 1953; Fischer-Schrel and Hoffman, 1988; Gardner and Pruell, 1987; Hinton *et al.*, 1992; Ferguson, 1989; Adams *et al.*, 1990; Cormier and Racine, 1990; Hinton *et al.*, 1978; Hinton and

Lauren, 1990a; Hilden and Rapport, 1993; Johnson *et al.*, 1992; Leino *et al.*, 1987; Longwell and Hughes, 1980; Klontz *et al.*, 1985; Reichenbach-Klinke, 1973; Roberts, 1989; Yamashita *et al.*, 1990; Pearce and Despres-Patanjo, 1988; Kent *et al.*, 1988; Koehler, 1989; Koehler, 1991; Kotak *et al.*, 1992; Khan and Thulin, 1991; Khan *et al.*, 1992; Kierstead *et al.*, 1990; Minchew and Yarbrough, 1977; Murugesan *et al.*, 1993; Myers *et al.*, 1992; Narain, 1990; Nagel *et al.*, 1992; Overstreet, 1988; Malins *et al.*, 1988; Laurent and Perry, 1991; Lauren *et al.*, 1991; Myers *et al.*, 1990; Parsons, 1990; Phillipart *et al.*, 1988; Roskam, 1965; Schoor and Couch, 1979; Secombes *et al.*, 1991; Simpson *et al.*, 1989; Simpson, 1992; Sindermann, 1979; Skinner, 1982; Sloof, 1982; Solangi and Overstreet, 1982; Stott *et al.*, 1981; 1983; Thiagarajah *et al.*, 1989; Vethaak, 1989; Vethaak and Meer, 1991; Vethaak *et al.*, 1992; Watermann and Kranz, 1992; Wester and Vos, 1986).

1. Diagnosis

The principles involved in making a diagnosis are the same in the field studies as they are following laboratory exposure. As the pathologist usually does not have the opportunity to see the harvested fish, it is essential that important information about the fish be recorded at the time of sampling and submitted with the biological material (Burckholer and Kennedy, 1993). If possible, the prevalence of background disease should be specified when samples are submitted. The more information provided to the pathologist, the more likely the chances of accurate results. For example, a lump on the skin of a fish cannot be considered a tumor unless histopathological evaluation of the specimen has been made (Gardner *et al.*, 1989; Hard *et al.*, 1979; Harshbarger and Clark, 1990; Hawkins *et al.*, 1988; Hawkins *et al.*, 1990; Hayes *et al.*, 1990; Kimura and Ando, 1986; Kinae *et al.*, 1990; Krantz and Dethlefsen, 1990; Murchenalo and Wolke, 1991; Onwumere and Oladimeji, 1990; Pierce *et al.*, 1978). Tumorogenicity of environmental factors has been addressed by a number of other authors (Kirby *et al.*, 1992; Cooper *et al.*, 1991; Couch, 1991; 1993; Dethlefsen and Watermann, 1980; Down and Leatherland, 1989; Smith *et al.*, 1979; Smith *et al.*, 1989; Stehr *et al.*, 1988; Stehr and Myers, 1990).

2. Monitoring

Using histopathology as a monitoring tool of fish health may give useful data concerning the disease prevalence at a specific point in time. The question of the positive predictive value of histopathology in monitoring changes has not yet been addressed, and there is insufficient literature to critically evaluate this issue. When evaluating direct histopathological effects, the results are unlikely to show specific toxicant effects, unless contaminants are present at near fatal concentrations (Johnson and Bergman, 1984). The sampling does provide information concerning age, structure and fecundity, which may be directly affected by toxicants (Hinton and Lauren, 1990b). However, when histopathological evaluation is

undertaken on a regular basis, it is possible to distinguish normal variations, such as those related to sex and time of the year, from toxicant-dependent changes (Myers *et al.*, 1987). Comparison of direct (toxicant-dependent) and indirect (background disease) lesions over time can lead to very strong associations (Lilienfeld and Lilienfeld, 1980).

3. Sensitivity

The sensitivity of histopathology depends upon the questions asked and the endpoints evaluated. Pathology is extremely sensitive when describing tissue changes from what is considered normal (Courtney and Couch, 1984). In fact, the increased sensitivity of histopathology instead of observation with the naked eye is analogous to using a telescope to evaluate stars on a clear night. With the telescope not only can one see better definition and resolution of the stars, but also see stars not visible to the naked eye. In addition, in most cases where fish are showing clinical signs or there are visible changes to the naked eye, histopathology is the most sensitive method of further defining the disease process.

4. Specificity

The specificity of histopathology has been overlooked in some situations. Gross descriptions of tumors (*tumor* - swelling) in fish do not help us in determining the tumor type or disease process (Hendricks, 1982). Indeed, without classification, it is impossible to determine the *a priori* risks with respect to cancer in the target species (Brecher, 1997). Histopathology can define the nature and quality of the tumor as inflammatory or neoplastic. In addition, the type of neoplasia and the cause of the inflammation may become apparent (Ferguson, 1989). Without histopathological evaluation, lumps and masses, such lesions as caused by fish hooks, parasites, injuries and tuberculosis, may be incorrectly recorded as cancer, and the mine upstream incorrectly blamed for their induction.

5. Best Use

The best use of histopathology in the field is two fold: (1) to attempt to define the cause of death in fish that die, and (2) to define the specific nature of disease patterns so that temporal-spatial comparisons can be made.

Histopathology adds little to the picture when the toxicant is known and a less expensive toxicity test is available, or when preservation of the specimens is impossible. It is not suited as an early warning system since many changes at the early stages of exposure would be either at the adaptive or maladaptive physiological level. Only when severe organ damage has occurred would florid lesions likely occur. In light of these limitations, histopathology should not be considered as a stand alone monitoring tool (Villeneuve *et al.*, 1994).

C. Relationship of Histopathology to other Biomarkers

There has been considerable debate concerning the terminology for bioindicators and biomarkers. For this document a biomarker will be defined as a biological marker of toxicant-induced toxicity (McCarthy and Shugart, 1990). Histopathology can be viewed as an endpoint or bioindicator that indicates a biomarker's response. In this case, histopathology may be used as a useful bioindicator when a biomarker is used as a sentinel, surrogate or predictor of environmental effects on individuals and populations (Hinton and Lauren, 1990). In such a way, histopathology may be used in biomarker-based monitoring of environmental contamination. However, the species, exposure-response and lesions must be adequately defined to enable surveillance, hazard assessment, regulatory compliance and remediation efforts to use histopathology as a bioindicator in a biomarker-based program (Hinton *et al.*, 1992).

There are situations where histopathology has been used in conjunction with other bioindicators. Defective development and hepatic histopathology have been positively correlated with hepatic EROD concentrations in lake sturgeon (*Acipenser fulviens*) taken from polluted and unpolluted sites (Branchaud *et al.*, 1995; Rousseaux *et al.*, 1995). These correlations represent *ad hoc* analyses of cross-sectional surveys. Unfortunately, correlations and cross-sectional studies do little to assist us with causality, as the correlation is probably related to a common function of the disease process, hence the variables correlated are not independent (Martin *et al.*, 1987).

Folmar *et al.* (1993) examined the relationships between the pathology and serum chemistry measurements for brown bullheads, *Ameiurus nebulosus*, by correlation and discriminant function analysis. The toxicological impact of uranium was evaluated through altered hematocrits, rates of parasitism and histopathological changes. They observed no apparent correlation between measurements, which may have been a function of exposure concentration rather than a lack of response. As correlation is a very crude tool in the effort to determine causality (Lilienfeld and Lilienfeld, 1980), there is a definite need to relate histopathological findings with biomarkers over time.

D. Data Gaps

1. Experimental

a) Morphological pathology

As shown in Table 1 (Section IV.A.4), the histopathological evaluation the effects of metals on the gills has been evaluated extensively in rainbow trout for chromium, zinc, mercury, ammonia and nickel. However, the histopathology of gill effects due to copper, cadmium, cyanide, lead and arsenate has not been documented well in all species. In order to fill all data gaps in fish histopathology, the determination of organ effects due to metals should encompass as many species as possible and exposure to a wide range of metals at different concentrations. Nevertheless, fish histopathology has a bias towards the effects of metals on gills compared to effects on other organs. Quantitative measurement of gill lesions using morphometry and stereology should be possible (Evans *et al.*, 1991) as the tissue edges are well delineated. It would be necessary to use very thin sections (plastic embedding) for these studies. The most practical method of generating quantitative data is through ranking of severity. These ranked ordinal data can then be transformed through using an arcsine or log transformation, and if the data are then normal in distribution, analyzed using parametric statistics (Krewski and Franklin, 1991). Alternatively, non-parametric evaluations can be made (Daniel, 1978).

The following studies need to be undertaken to give the appropriate building blocks for extrapolation of laboratory findings into the field:

- dose-response effects (including descriptions, NOECs, etc.) for tailings, metals and other contaminants in a number of teleost species;
- bioavailability of tailings, metals and other contaminants in a number of species (see Hrudey *et al.*, 1996 for mammals);
- physiologically-based pharmacokinetic modeling for target tissue dosing (Medinsky and Klaassen, 1996);
- postmortem autolysis time to obscure the lesions in fish (see Rousseaux *et al.*, 1992 for mice);
- time to lesion development in all organs in fish (see Cheville, 1983 for mammals); and,
- further determine the chemical carcinogenesis response (Hendricks, 1982).

b) Clinical Pathology

The specific data gaps that need to be filled in clinical pathology as they relate to mining industry are:

- relationship of specific serum chemistry and hematology to histopathology; and,
- creation of tables of “normal values” in all teleost species.

c) Teratology

The specific data gaps that need to be filled in teratology as they relate to mining industry are:

- aquatic teratogenic response definition; and,
- dose-response effects to specific contaminants.

2. Field Studies

As the peer-reviewed literature focuses on the histopathology of fish in experiments, it is important that further histopathological data be collected in field studies. The following are suggested to fill some of the data gaps:

- baseline information concerning disease prevalence for a number of teleost species to be monitored;
- background teratogenesis in all teleost species of interest;
- normal clinical pathology and hematology tables for all teleost species to be evaluated;
- positive predictive value determinations need to be made concerning histopathological evaluations over time; and,
- determination of the most sensitive histological endpoints to be evaluated in the field.

VI. UTILITY OF HISTOPATHOLOGY

A. *Rationale for when to Use Histopathology*

1. **Diagnostic Assessment of Fish Kills**

The diagnostic methodology described above can be used to help solve the problem in fish kills when the causative agent is not known. In cases of pathognomonic changes, microscopic evaluation alone may provide the etiology (see Section IV.A.2, Table 1). Sometimes the histopathology can indicate a cause of death postmortem; however, this first pass does not always elucidate the cause.

The Toxicity Identification Evaluation (TIE) test can be enhanced by using chemical analysis, evaluating other biomarkers, and conducting literature searches on the compounds likely to have caused the post-mortem changes. Following selection of the suspected causative compound, a modified Koch's response to the exposure can be evaluated (Tones and Rousseaux, 1992). By this method, experimental exposure to each of the suspect compounds at doses approximating the water that the fish died in, a match can usually be found. The definition of the cause can be summarized by:

1. histopathological description of the lesions;
2. chemical evaluation of the water;
3. toxicological literature review with respect to the compounds found in the water;
4. selection of the most likely candidate(s);
5. experimental exposure of test fish to this candidate toxicant;
6. histopathological evaluation of the exposed fish;
7. if the same lesions are seen following exposure, then causality is confirmed;
8. if no lesions are seen, repeat until a match is found.

Obviously, less costly Toxicity Identification and Evaluation test methods may be considered first; however, confirmation of the toxicant can only be unquestionably verified in the target species.

2. **Defining the Dose-Response in Experiments**

The classical LC₅₀ (Lethal Concentration) does little to increasing our knowledge base apart from defining a lethal dose. Of more importance in extrapolating laboratory results to the field is to determine a Lowest Observable Effect Concentration (LOEC) or a No Observed Adverse Effects Concentration (NOAEC) in the test fish. By establishing such a

concentration, remediation and regulatory efforts are more precise and less expensive. Histopathology adds sensitivity to the LC₅₀ by allowing determination of the ED₅₀ (Effective Dose) or toxicological endpoints (Haschek and Rousseaux, 1991). In addition, valuable “baseline” lesions are described to add to the knowledge base to be extrapolated into the field.

Histopathology should be considered for use in a suite of endpoints in toxicity studies (Villeneuve *et al.*, 1994). Physiological abnormalities and structural changes will aid in the definition of a concentration of effluent, or leachate, that does not appear to cause any adverse effect.

Dose-reponse experiments can utilize the methods developed in teratology to analyze for abnormal morphology. There are a number of reports that relate toxicants to pollutants in the literature (Couch *et al.*, 1979; Mukhopadhyay and Konar, 1988; Sloof, 1982; VandeKamp, 1977; Weis and Weis, 1976; 1989; Zaki and Saad, 1987).

3. Field Studies

Field studies may relate histopathological changes to pollutant concentrations (Foerlin *et al.*, 1990), or relate enzyme concentrations to histopathological changes with respect to polluted and not polluted sites (Rousseaux *et al.*, 1995). Field studies may also include baseline, operational and post-closure assessments for industry. The importance of histopathology depends upon the program in place and the baseline of effects already taken. As previously mentioned, it is necessary to evaluate general histopathology over a number of time points because of the confounding variable of background disease patterns.

B. When Histopathology is of Little Use

The following list contains some situations where histopathology is unlikely to add value to the study in question:

1. When the toxicant is known and other cheaper validated toxicity tests for this type of compound are available, such as Microtox®, *Daphnia magna*, etc.;
2. When preservation of the specimens is not possible i.e. the specimens are frozen (although some information can be obtained from these specimens in some cases), the specimens are autolysed, or the specimens have been traumatized during dissection.

C. Approaches to Histopathology

Pathology atlases such as Takashi (1982), general pathology texts such as Roberts (1989), or specific organ-related articles (e.g., Kosaric *et al.*, 1993) are useful items for those commencing in the field. There are a number of ways to approach histopathology, some of which have been reviewed (Neilson *et al.*, 1990; Southgate, 1979; Wester and Vos, 1986; Wester and Canton, 1991). These range from individual organ evaluation, which may also use ultrastructural and morphometric techniques, to multiple tissue evaluation. In the case of establishing the health of the fish, it is necessary to evaluate *all* tissues, not just one or two. If fish are large, and time constraints prevent submission of samples of all organs, then the following tissues should be submitted: liver, kidney (anterior and posterior), gills, gonads and spleen. Regardless of the sampling method, a standardized classification scheme should be used (Reimschuessel *et al.*, 1992). Finally, it is necessary to be aware of background disease and its importance in the evaluation process (Gaines and Rogers, 1975; Lafayette, 1975; Wolf *et al.*, 1972; Yasutake *et al.*, 1965).

When histopathology is being used as a tool in the field or in the lab, it is essential that it is not used alone, and that other enzymic and blood tests are used. In addition, it essential that adequate numbers of fish are presented for evaluation. In the case of dose-response studies, a number of six should be considered.

D. The Limitations of Pathology

As with all disciplines, pathology has limitations. This section addresses those limitations that do not relate to specimen submission and processing.

1. Temporality

Pathology examines the cells, organs and organism at a fixed point in time. This means that the changes described are limited to the tissue supplied at the one time point as multiple samples cannot be taken from a single fish over time. For this reason, any time related bias can influence the results of the examination. For example, a short but sudden increase in metal concentration may give a positive tissue damage indicative of acute toxicity, but does little to show the long-term effects of tailings on the fish population. The corollary also holds true, ie. cumulative substances, such as mercury, may be in concentrations that do not produce acute toxicity but result in hispathological changes following chronic exposure.

2. Structure and Function

The beauty of pathology is often thought to be related to what we can see. “A picture says a thousand words” certainly is an expression that holds true here. However, it is important to note that there are two basic toxicological responses shown by fish: structural alterations and

functional alterations. Before addressing the dissonance between the two, it is important to reiterate the dose-response curve and how a progression of events can usually lead to death.

The dose-response progression of exposure through physiological and morphological adaptation and change, through to death, assumes that all other aspects of population biology, physiological function, and disease status are held constant. However, different stages of reproduction, sampling season, and concurrent disease need to be considered when comparing results among studies.

This progression shows that functional changes usually occur before morphological changes; however, this is not always the case. Rarely do structural changes occur that have little or no functional consequence for the fish. Usually, the problem related to structure and function pertain to the diagnostic world where a poisoning has occurred without leaving a morphological foot print. Regardless, it can be seen that death is not the endpoint that we wish. In designing laboratory experiments it is valuable to dose fish in the window that will cause functional toxicity with morphological alterations. These doses provide the most useful data.

3. Relating Morphological Changes to Causes

Relating morphological changes to causes is rarely easy. There are few toxicants that leave a distinct fingerprint. However, with other input from biologists and the results of specific organ function, a cause can often be determined. Sometimes morphological changes are more an indication of decreased fish health than direct toxicity, and as such pathology is an excellent tool to assist in determining the health of fish.

4. Concurrent Disease

In the field, disease is a naturally occurring event (Yasutake, 1970). Indeed, in every day life disease occurs in our own species. An increase in the common cold and influenza during the changes of the season is recognized among ourselves; however, it must be recognized that wild populations go through similar cycles. Pathology is an excellent method of determining concurrent disease. However, there are problems associated with concurrent disease as the disease process may obscure subtle histological changes in the tissues. For example, mild contaminant-related liver changes may be obscured by a heavy parasite load that affects the liver.

5. Confounding Variables

Pathologists must deal with the problem of confounding variables. Although this difficulty is partially addressed in the section above, positive findings may be related to other events than the mine in question. For example, introduction of a new viral disease may result in changes that could be attributed to mining practice rather than the causative agent. Another source of confusion may be from systematic bias. As previously discussed, pathology and pathological determination is subjective and is in part a result of the experience of the pathologist. By using multiple laboratories or different pathologists over a time frame (e.g., baseline, operational and post-closure), operator bias may be introduced and confound the results. To reduce this confounding factor, it is wise to re-read other previously viewed tissues.

E. Advantages vs. Disadvantages of Histopathology

The following table (Table 5) summarizes the advantages, disadvantages and limitations of fish histopathology:

Table 5: The advantages, disadvantages and limitations of fish histopathology

The Advantages, disadvantages and limitations of Fish Histopathology	
ADVANTAGES	
Advantages of Histopathology	Comments/ Examples
<ul style="list-style-type: none"> • Great discriminating power and speed of the approach • The precision with which lesions can be identified 	Small adults or fish larvae properly oriented for hemisection (Courtney and Couch, 1984) yield samples through major viscera that can be viewed on a few histological slides. Larger specimens containing lesions can include both the affected and "normal" tissues (Bucci, 1991).
<ul style="list-style-type: none"> • Rapid sampling of many potential sites of injury i.e. many organ systems can be evaluated following collection 	A study by Wester and Canton (1986) showed morphological changes in gonads (intersexuality), liver, kidney, pituitary, thyroid, spleen, and heart of medakas <i>Oryzias latipes</i> that had undergone long-term exposure to β -hexachloro-cyclohexane.
<ul style="list-style-type: none"> • Indicates effects, not just exposure 	This is of particular interest when attempting to define a dose-response and target site of action of a toxicant or toxin

The Advantages, disadvantages and limitations of Fish Histopathology	
	(Tones and Rousseaux, 1992).
<ul style="list-style-type: none"> Quantitative measurements can be made as to the degree, temporality and quality of lesions seen 	Quantitative morphometry and stereology is useful in some situations to show statistical differences among treatments, time of sampling, and other factors (Evans <i>et al.</i> , 1991).
<ul style="list-style-type: none"> Disease patterns can be followed in the field 	Histopathology, in conjunction with other measurements of health, give an excellent picture of fish health (Ferguson, 1989).
<ul style="list-style-type: none"> Temporal development of disease can be determined 	Longitudinal studies can help define the disease dynamics in specific species, times and places (Lilienfeld and Lilienfeld, 1980).
<ul style="list-style-type: none"> Well validated and easily available methods are available for preservation and staining 	Routine tissue processing and staining can be done at almost any pathology laboratory. Evaluation of malformations following appropriate staining (Rousseaux, 1985).
<ul style="list-style-type: none"> Both direct and indirect effects can be determined 	Evaluation of multiple tissues may incriminate a toxicant even though the initial process seen appears unrelated (Ruben and Rousseaux, 1991).
<ul style="list-style-type: none"> High sensitivity at various levels (light and electron microscopy) 	Changes not seen in the field can be visualized under the light microscope. Ultrastructural evaluation is even more sensitive (Kumar <i>et al.</i> , 1992).
<ul style="list-style-type: none"> Data can be correlated with other biomarkers 	Abnormal morphology can be correlated with enzymatic changes, such as EROD (Branchaud <i>et al.</i> , 1995; Rousseaux <i>et al.</i> , 1995).
<ul style="list-style-type: none"> Tissue can be preserved and analyzed at the most suitable time 	Fixation is easy and storage straight forward (Bucci, 1991).
<ul style="list-style-type: none"> Changes can be assessed in animals that are too small to dissect for biochemical purposes 	Important in the monitoring of eggs and larvae and also of adults of numerous small fish species that have value as sentinel organisms (Ferguson, 1989).
DISADVANTAGES	

The Advantages, disadvantages and limitations of Fish Histopathology	
Limitations of Histopathology	Comments/ Examples
<ul style="list-style-type: none"> • Subjective nature of morphological studies, the evaluation is as much of an art as a science which often results in operator bias 	<p>Variations among investigators is reduced when slides are read by a single individual and specific criteria for classification of lesions are applied uniformly (Bucci, 1991). Training is vital (Leader, 1991).</p>
<ul style="list-style-type: none"> • If there is inadequate prior knowledge of the normal state of a given species 	<p>Errors in histopathologic assays can result if prior knowledge of the normal state for a given species or the training of the evaluator is inadequate.</p>
<ul style="list-style-type: none"> • The paucity of carefully executed descriptive studies of the locale and morphology of individual cell types 	<p>There is tremendous variation when micrographs of rainbow trout hepatocytes (Hampton <i>et al.</i>, 1985) are compared with those of Atlantic tomcod <i>Microgadus tomcod</i> (Smith <i>et al.</i>, 1979). The seasonal variation of tissue histology is not known for all species.</p>
<ul style="list-style-type: none"> • A source of error in interpretation relating to seasonal nutritional and hormonal cycles 	<p>Endogenous levels of estradiol affect lipid stores in the liver and morphology of the endoplasmic reticulum in hepatocytes (Van Bohemen <i>et al.</i>, 1981). Factors such as the nutritional state of the animal also affect liver histology. Starvation induces pronounced alterations of liver histology in fishes (Gas, 1973; Langer and Storch, 1978; Leatherland, 1982; Segner and Moeller, 1984).</p>
<ul style="list-style-type: none"> • Can only show effects at a single point in time 	<p>Reversibility, progression and prognosis for individuals and a population is difficult with a single sampling time point.</p>
<ul style="list-style-type: none"> • Cause and effect conclusions often require supporting data and are difficult to demonstrate for specific contaminants 	<p>Not all contaminants leave a finger print and the animal can only respond in a limited number of ways (Thomson, 1988; Ferguson, 1989). It is necessary to assay tissues for the suspected contaminant in addition to histopathological evaluation</p>
<ul style="list-style-type: none"> • Confounding variables may decrease sensitivity 	<p>Concurrent disease, nutritional status, and seasonal variation may obscure the subtle changes seen attributable to a toxicant (Ruben and Rousseaux, 1991).</p>

The Advantages, disadvantages and limitations of Fish Histopathology	
<ul style="list-style-type: none"> • Because of the lack of sensitivity in the field (confounding variable) and biological variation, a large number of fish must be used 	In addition, a baseline of disease in fish
<ul style="list-style-type: none"> • There are few qualified fish pathologists 	
<ul style="list-style-type: none"> • Cost 	questionable cost effectiveness in monitoring studies.
<ul style="list-style-type: none"> • Confounding issues in the histochemical assessment of anthropogenic toxicity with respect to toxins released by either enteric or exogenous microorganisms (hypothetical - Hinton and Lauren, 1990a) 	Gut-derived endotoxins in the portal venous system are usually removed by K�pffer cells in sinusoids of the liver in mammals, but at least some species of fish do not have these phagocytic cells (McCuskey <i>et al.</i> , 1986). Although the exudates of some freshwater blue-green algae are known to cause liver necrosis in mammals (Carmichael, 1988), little is known about the effects of these toxins on fish. Bacterial endotoxins have been shown to enhance the hepatotoxicity of allyl alcohol in mammals (Sneed <i>et al.</i> , 1997)

F. Practitioners and Availability

As previously mentioned, the rigorous requirements of training a pathologist means that teleost histopathologists are not common. Part of the reason for the scarcity of pathologists lies in the lack of a strong market for fish histopathology services.

The basic training of a pathologist is structured so that a transfer to the specialized field of teleost pathology can be done with minimal effort. At present, however, the veterinary diagnostic pathology thrust of the 70's has been reversed with closure of a number of laboratories. In addition, the employment position is equally difficult for some human pathologists. Once a definite market develops in fish pathology, we can expect a movement of highly qualified individuals into this field.

At present in Canada, the following institutions can service the industry:

Commercial

1. GLOBALTOX INTERNATIONAL CONSULTANTS INC.
2. RSGConsulTest Inc.
3. VPL Ltd

Institutional

1. University of Guelph
2. University of Saskatchewan
3. University of PEI
4. Université de Montréal
5. Department of Fisheries and Oceans
6. Provincial Veterinary laboratories

There are undoubtedly a few individual pathologists within other institutions not mentioned who would also have the expertise necessary to undertake the work.

G. Costs and quality issues

1. Preparation of Specimens

To obtain the most cost effective results, it is essential to correctly take, preserve, package, send, and dispose of specimens. An excellent training video, which was originally developed for veterinary and animal health technician students can be obtained from the University of Saskatchewan for \$10-20. The title is: *“The Trilogy of Specimen Submission: It’s as easy as One, Two, Three.”* Another useful training tool for individuals in the field is entitled: *“The Post-Mortem Examination of Fin-Fish.”* This can be purchased from the University of Prince Edward Island, Atlantic Veterinary College for \$60.

If specimens cannot be collected well, or cannot be rapidly fixed, it is NOT cost effective to attempt histopathological evaluation.

2. Number of Specimens Required

The number of specimens required depends on the endpoints to be evaluated. If the exposure is known and the lesions quite specific to the exposure, six exposed and six control fish would suffice. However, in situations of population baseline studies, up to 200 fish may be required to adequately determine the disease status of the population. In the case of die-offs, as few as a single fish can help the pathologist clinch the diagnosis.

3. Transport of Specimens

As previously mentioned, there are specific transport requirements for the transport of tissue specimens fixed in formalin. An economical method of transport is to use coolers and have the laboratory return them for future use.

4. Cost

The cost of pathological and histopathological evaluation depends on what detail is requested. Usually, if an evaluation of all tissues, a detailed description, and a morphological and etiological diagnosis are requested, the cost can run from \$150-225 per fish depending on the number of samples and the complexity of the study. Other prices may be lower; however, the reporting is not as elaborate or informative.

Individual tissues can be evaluated at a lower cost. The cost to trim, process, make a slide with routine hematoxylin and eosin stain can range from \$13.50-15.00 depending on the laboratory, tissue, stain and the question asked. Evaluation, again, depends on the question asked and can be charged at an hourly rate or a unit price. Government and University institutions may be able to give better pricing for evaluation. However, with cost recovery and increased work loads this is not likely to continue.

5. Response Time and Reporting

In commercial operations, where response time and service is their *raison d'être*, the response time is optimized. Usually, a verbal response concerning individual tissues can be given in 72 hours and a written report within three weeks. Publicly funded institutions, on the other hand, operate under different forces, hence the reporting time may differ.

H. Optimizing Histopathology

The most cost-effective method of using histopathology is in conjunction with other biomarkers. By evaluating all the data in conjunction with histopathology, a better evaluation of fish health can be made.

I. The Use of Fish Histopathology in Filling Data Gaps

Fish histopathology should be considered in filling disease-related, toxicant-related and toxin-related data gaps. Often the gaps are so large that basic parameters such as growth maturation and reproduction are not known, let alone background disease and abnormal development rates. Histopathological evaluation gives multiple endpoints to describe baseline findings in such baseline studies.

J. What Can be Learned From the Analysis

Histopathology can be used in the following ways:

- as a diagnostic tool
- as an experimental tool
- as a broad scan evaluation of fish health

As a diagnostic tool, there is no better method of determining causality than using histopathology. As an experimental tool, histopathology can generate useful, and sometimes pivotal, data. As a broad spectrum scan of fish health, it gives us abundant data; however, interpretation is difficult if there is no follow-up. To re-iterate, the only way of properly establishing the status of fish health is to use a suite of tests including histopathology in conjunction with the usual population evaluations.

VII. CONCLUSIONS

Histopathology can be a powerful tool in the definition of disease caused by toxicants, in establishing background levels of disease, and in defining the dose-response toxicity to leachates and effluents in the laboratory. Like all other methods used to determine fish health, histopathology cannot be considered to be the silver bullet of environmental monitoring. For this reason, histopathology should be considered as one in a suite of tools and testing methods to evaluate fish health, unless there is a specific die-off problem. If specimens cannot be properly collected, or cannot be rapidly fixed (i.e. Bouin's fixative or a 10:1 formalin to tissue ratio), it is NOT cost effective to attempt a histopathological evaluation.

VIII. RECOMMENDATIONS

The following recommendations are given with respect to field work and the mining industry:

A. *Recommended Level of Action*

- Large numbers and greater varieties of fish species should be collected on an annual basis for more detailed morphological evaluation and verification of histopathology methodologies in the field.
- Sampling should be conducted on a regular basis in a wide variety of fish species to establish seasonal variation on the effects of naturally variable habitat (food supply, etc.)
- Once these “general baseline data” have been established, an additional effort should be concentrated in site-specific compromised environments.

B. *Histopathology as a Tool for the Mining Industry*

- Histopathology should be considered in the suite of tools used in helping define the background, or baseline, health status of the population;
- Histopathology should be considered for use in operational and post-closure studies only in situations where there are histopathological data present (baseline for operational; operational for post-closure);
- Histopathology should be used routinely in the case of fish die-off;
- Histopathology should be incorporated into fish health studies before the field work begins rather than as an “add on;”
- Histopathological evaluation should be limited to qualified personnel; and,
- Histopathology should be used in defining the No Observed Adverse Effect Level (NOAEL) in laboratory studies on effluent and leachates.

IX. BIBLIOGRAPHY

A. *Grey Literature:*

- Adams, S.M., Shugart, L.R., Southworth, G.R., and D.E. Hinton. (1990). Application of bioindicators in assessing the health of fish populations experiencing contaminant stress. **In:** Biomarkers of Environmental Contamination. J.F. McCarthy and L.R. Shugart (eds.). Lewis Publishers; Chelsea, Michigan. pp. 333-354.
- Arnold, D.L., Grice, H.C., and D.R. Krewski. (1990). Handbook of *in Vivo* Toxicity Testing. Academic Press; Toronto. pp. 678
- Ashley, L.M. (1975). Comparative fish histology. **In:** The Pathology of Fishes. W.E. Ribelin and G. Migaki (eds.). University of Wisconsin Press; Madison, Wisconsin. pp. 3-32.
- Ball, J. N. and B.I. Baker. (1969-1970). The pituitary gland: Anatomy and histophysiology. **In:** Fish Physiology. W.S. Hoar and D.J. Randall (eds). Academic Press; New York Vol. 2. pp. 23.
- Bengtsson, B.E. (1975). Vertebral damage in fish induced by pollutants. **In:** Sublethal Effects of Toxic Chemicals on Aquatic Animals. Koeman, J.H. and J.J. Strik (eds.). Elsevier Publications; New York, New York. pp. 23-30.
- Bryden, D.I. (1988). Fish Diseases: Refresher Course for Veterinarians - Proceedings (106) 23-27 May 1988. University of Sydney, Sydney.
- Bucci, T.J. (1991). Evaluation of altered morphology. **In:** Handbook of Toxicologic Pathology. W.M. Haschek and C.G. Rousseaux (eds.). Academic Press; San Diego. pp. 23-35.
- Cheville, N.F. (1983). Cell Pathology (2nd ed). The Iowa State University Press; Ames, Iowa. pp. 681
- Cormier, S.M., and R.N. Racine. (1990). Histopathology of atlantic tomcod: A possible monitor of xenobiotics in Northeast Tidal rivers and estuaries. **In:** Biomarkers of

- Environmental Contamination. J.F. McCarthy and L.R. Shugart (eds.). Lewis Publishers; Chelsea, Michigan. pp. 59-73.
- Cotran, R.S., Kumar, V., and S.L. Robbins (1989). Pathologic Basis of Disease. W.B. Saunders Company, Division of Harcourt Brace Jovanovich Inc; Philadelphia, PA. pp. 1519
- Couch, J.A. (1975). Histopathological effects of pesticides and related chemicals on the livers of fish. **In:** The Pathology of Fishes. W.E. Ribelin and G. Migaki (eds.). University of Wisconsin Press; Madison, Wisconsin. pp. 559-584.
- Daniel, W.W. (1978). Applied Nonparametric Statistics. Houghton Mifflin Company; Boston. pp. 503
- Dodd, D.C. (1991). The pathologist in toxicologic testing and evaluation. **In:** Handbook of Toxicologic Pathology. W.M. Haschek and C.G. Rousseaux (eds.). Academic Press; San Diego. pp. 9-22.
- Ellis, A.E. (1985). Fish and Shellfish Pathology. Academic Press; London. pp. 412
- Evans, M.J., Shami, S.G., and M.R. Wells. (1991). Quantitative techniques for morphological evaluation. **In:** Handbook of Toxicologic Pathology. W.M. Haschek and C.G. Rousseaux (eds.). Academic Press; San Diego. pp. 37-49.
- Ferguson, H.W. (1989). Systemic Pathology of Fish: A Text and Atlas of Comparative Tissue Responses in Diseases of Teleosts. Iowa State University Press; Ames, Iowa.
- Foerlin, L., Celander, M., Norrgren, L., Balk, L., Hoerding, J., Hellstroem, A., and O. Ljungberg. (1990). An initial study on liver lesions, biochemical changes and pollutant concentrations in Brown Trout caught in a small Swedish river. **In:** Physiological and Biochemical Approaches to the Toxicological Assessment of Environmental Pollution.
- Gad, S. and C.S. Weil. (1988). Statistics and experimental design for toxicologists. Telford Press; Caldwell, New Jersey. pp. 376

- Gaines, J.L. and W.A. Rogers. (1975). Some skin lesions of fishes. **In:** The Pathology of Fishes. W.E. Ribelin and G. Migaki (eds.). University of Wisconsin Press; Madison, Wisconsin. pp. 429-442.
- Gardner, G.R. (1975). Chemically induced lesions in estuarine or marine teleosts. **In:** The Pathology of Fishes. W.E. Ribelin and G. Migaki (eds.). University of Wisconsin Press; Madison, Wisconsin. pp. 657-694.
- Groman, D.B. (1982). Histology of the Striped Bass. American Fisheries Society; Bethesda, Maryland. pp. 116
- Haschek, W.M. and C.G. Rousseaux. (1997). Fundamentals of Toxicologic Pathology. Academic Press; San Diego, CA. (In Press)
- Haschek, W.M. and C.G. Rousseaux. (1991). Handbook of Toxicologic Pathology. Academic Press; San Diego, CA.
- Hawkes, J.W. (1977). The effects of petroleum hydrocarbon exposure on the structure of fish tissues. **In:** Fate and effects of petroleum hydrocarbons in marine ecosystems and organisms. D.A. Wolfe (ed.). Pergamon Press; New York. pp. 115-128.
- Hayes, A.W. (1994). Principles and Methods of Toxicology. Third Edition. Raven Press; New York.
- Hendricks, J.D. (1982). Chemical Carcinogenesis in Fish. **In:** Aquatic Toxicology: Volume 1. Aquatic Toxicology Series. L.J. Weber (ed.). Raven Press; New York. pp. 149-211.
- Hendricks, J.D. (1979). Appendix II. Effect of various herbicides on histology of yearling coho salmon. **In:** Effects of Selected Herbicides on Smolting of Coho Salmon. H.W. Lorz, S.W. Glenn, R.H. Williams, C.M. Kunkel, L.A. Norris, and B.R. Loper (eds.). U.S. EPA 600/3-79-071; Corvallis Environmental Research Laboratory. pp. 90-93.
- Hill, R.B. and M.F. LaVia. (1980). Principles of Pathobiology. Oxford University Press; Oxford. pp. 347
- Hinton, D.E., Baumann, P.C., Gardner, G.R., Hawkins, W.E., Hendricks, J.D., Murchelano, R.A., and M.S. Okihiro. (1992). Histopathologic Biomarkers. **In:** Biomarkers:

Biochemical, Physiological, and Histological Markers of Anthropogenic Stress. R.J. Huggett, R.A. Kimerle, P.M. Mehrle, and H.L. Bergman (eds.). Lewis Publishers; Chelsea, Michigan. pp. 155-210.

Hinton, D.E., Kendall, M.W., and B.B. Silver. (1973). Use of histologic and histochemical assessments in the prognosis of the effects of aquatic pollutants. **In:** Biological Methods for the Assessment of Water Quality. ASTM STP 528. *Am. Soc. Testing and Materials*. pp. 94-198.

Hinton, D.E. and D.J. Lauren. (1990a). Integrative histopathological approaches for detecting effects of environmental stressors on fishes. **In:** Biological Indicators of Stress in Fish. S.M. Adams. (ed.). *Amer. Fish. Soc.*; Special Publication.

Hinton, D.E. and D.J. Lauren. (1990b). Liver structural alterations accompanying chronic toxicity in fishes: Potential biomarkers of exposure. **In:** Biomarkers of Environmental Contamination. J.F. McCarthy and L.R. Shugart (eds.). Lewis Publishers; Chelsea, Michigan. pp. 17-59.

Hrudey, S.E., Chen, W., and C.G. Rousseaux. (1996). Bioavailability in Environmental Human Health Risk Assessment. Lewis Publishers, Boca Raton, FA.

Jeffrey, E.H. (1991). Biochemical basis of toxicity. **In:** Handbook of Toxicologic Pathology. W.M. Haschek and C.G. Rousseaux (eds.). Academic Press; San Diego, CA. pp. 50-70.

Johnson, R.D. and H.L. Bergman. (1984). Use of Histopathology in Aquatic Toxicology: A critique. **In:** Contaminant Effects on Fisheries. V.W. Cairns, P.V. Hodson, and J.O. Nriagu (eds.). John Wiley & Sons; New York.

Jubb, K.V.F., Kennedy, P.C., and N. Palmer. (1985). Pathology of Domestic Animals, Volume 1 (3rd ed.). Academic Press; Montreal, pp. 574

Kennedy, H.D., Eller, L.L., and D.F. Walsh. (1970). Chronic effects of methoxychlor on bluegills and aquatic invertebrates. *U.S. Bur Sport Fish Wildl Tech Pap* 53.

Kerr, S.R. and L.M. Dickie. (1984). Measuring the Health of Aquatic Ecosystems. **In:** Contaminant Effects on Fisheries. V.W. Cairns, P.V. Hodson, and J.O. Nriagu (eds.). John Wiley & Sons; New York.

- Kirby, G.M., Hayes, M.A., Niimi, A.J., and M.C. Taylor. (1992). Significance of liver neoplasia in wild fish: Assessment of pathophysiological responses of a biomonitor species to multiple stress factors. **In:** Proceedings of the Eighteenth Annual Aquatic Toxicity Workshop; Ottawa, Ontario. *Can. Tech. Rep. Fish. Aquat. Sci.* **1863**: 106-116.
- Klaassen, C.D. (1996). Toxicokinetics. **In:** Casarett and Doull's Toxicology: The Basic Science of Poisons. Fifth edition. C.D. Klaassen (ed.). McGraw-Hill; New York. pp. 187-198.
- Klontz, G.W. (1985). Diagnostic methods in fish diseases: Present status and needs. **In:** Fish and Shellfish Pathology. A.E. Ellis (ed.). European Association of Fish Pathology. Academic Press; London, England. pp. 3-9.
- Klontz, G.W., Stewart, B.C., and D.W. Eib. (1985). On the etiology and pathophysiology of environmental gill disease in juvenile Salmonids. **In:** Fish and Shellfish Pathology. A.E. Ellis (ed.). European Association of Fish Pathology. Academic Press; London England. pp. 199-210.
- Krewski, D. and C. Franklin. (eds). (1991). Statistics in Toxicology. Gordon and Breach Science Publishers; New York. pp. 677
- Kumar, V., Cotran, R.S., and S.L. Robbins. (5th ed). (1992). Basic Pathology. W.B. Saunders Company; Toronto, ON.
- Lafayette, L.E. (1975). Gill lesions in freshwater teleosts. **In:** The Pathology of Fishes. W.E. Ribelin and G. Migaki (eds.). University of Wisconsin Press; Madison, Wisconsin. pp. 305-330.
- Leader, R.W. (1991). Toxicologic pathology: An introduction. **In:** Handbook of Toxicologic Pathology. W.M. Haschek and C.G. Rousseaux (eds.). Academic Press; San Diego, CA. pp. 1-7.
- Levin, S.A., Harwell, M.A., Kelly, J.R., and K.D. Kimball. (1989). Ecotoxicology: Problems and Approaches. Springer-Verlag; London.
- Lilienfeld, A.M. and D.E. Lilienfeld. (1980). Foundations of Epidemiology (2nd ed.). Oxford University Press; New York. pp. 375

- Lock, R.A.C. (1975). Uptake of methylmercury by aquatic organisms from water and food. **In:** *Sublethal Effects of Toxic Chemicals on Aquatic Animals*. J.H. Koeman and J.J. Strik (eds.). Elsevier Scientific; New York. pp. 61-80.
- Maronpot, R.R. (1991). Chemical carcinogenesis. **In:** *Handbook of Toxicologic Pathology*. W.M. Haschek and C.G. Rousseaux (eds.). Academic Press; San Diego. pp. 92-129.
- Martin, S.W., Meek, A.H., and P. Willeberg. (1987). *Veterinary Epidemiology: Principles and Methods*. Iowa State University Press; Ames.
- McCarthy, J.F. and L.R. Shugart. (1990). Biomarkers of Environmental Contamination. J.F. McCarthy and L.R. Shugart (eds.). Lewis Publishers; Chelsea, Michigan. pp. 457
- McCuskey, P.A., McCuskey, R.S., and D.E. Hinton. (1986). Electron microscopy of the cells fo the hepatic sinusoids in rainbow trout *Salmo gairdneri*. **In:** A. Kirn and D.L. Knook (eds.). *Cells of the hepatic sinusoid, Volume 1*. Küppfer Cell Foundation, Leiden, The Netherlands. pp. 489-494.
- Meyers, T.R. and J.D. Hendricks. (1985). Histopathology. **In:** *Fundamentals of Aquatic Toxicology*. G.M. Rand and S.R. Petrocelli (eds.). Hemisphere Publishing Corporation; Washington, D.C. pp. 283-331.
- Moeller, H. (1985). A critical review on the role of pollution as a cause of fish diseases. **In:** *Fish and Shellfish Pathology*. A.E. Ellis (ed.). European Association of Fish Pathology. Academic Press; London England. pp. 169-182.
- Moulton, J.E. (ed). (1978). *Tumors in Domestic Animals* (2nd ed). University of California Press; London, pp. 465
- Murugesan, A.G., Haniffa, M.A. Carrillo, M., Dahle, L., Morales, J., Sorgeloos, P., Svennevig, N., and J. Wyban. (1993). **In:** *From Discovery to Commercialization. Spec. Publ. Eur. Aquacult. Soc.* pp. 19
- Nagel, R, Becker, H., and R. Heitefuss. (1992). Toxicity of pesticides to aquatic vertebrates illustrated by the example of fish. **In:** *Beurteilung VonPflanzenschutzmitteln in Aquatischen Oekosystemen*. pp. 88-104.

- OECD. (1993). OECD Guidelines for the Testing of Chemicals; Volume 1. OECD; Paris.
- Porter, K.R. and M.A. Bonneville. (1973). Fine structures of cells and tissues. Lea & Febiger; Philadelphia. pp. 204
- Pritchard, J.B. and J.L. Renfro (1984). Interactions of xenobiotics with teleost renal function. **In:** Aquatic Toxicology: Volume 2 (ed.). Aquatic Toxicology Series. Raven Press; New York. pp. 51-106.
- Reichenbach-Klinke, H.-H. (1975). Lesions due to drugs. **In:** Pathology of Fishes. W.E. Ribelin, G. Migaki (eds.). Madison, Wis.; University of Wisconsin Press. pp. 647-656.
- Reichenbach-Klinke, H.-H. (1973). Reichenbach-Klinke's Fish Pathology: A Guide to the Recognition and Treatment of Diseases and Injuries of Fishes, with Emphasis on Environmental and Pollution Problems. T.F.H. Publications; Hong Kong. pp. 512
- Ribelin, W.E. and G. Migaki (1975). The Pathology of Fishes. University of Wisconsin Press; Wisconsin. pp. 1004
- Roberts, R.J. (1989). Fish Pathology - *Second Edition*. Bailliere Tindall; London, England.
- Rousseaux, C.G. and P.M. Blakley. (1991). Fetus. **In:** Handbook of Toxicologic Pathology. W.M. Haschek and C.G. Rousseaux (eds.). Academic Press; San Diego. pp. 937-981.
- Rousseaux, C.G. (1989). Proving your point: The elements of research in the biomedical sciences. University of Saskatchewan; Saskatoon. pp. 1-60.
- Rousseaux, C.G. (1988). Experimental Pathology. University of Saskatchewan; Saskatoon. pp. 1-250. (revised 1989 pp. 1-109).
- Ruben, Z. and C.G. Rousseaux. (1991). The limitations of toxicologic pathology. **In:** Handbook of Toxicologic Pathology. W.M. Haschek and C.G. Rousseaux (eds.). Academic Press; San Diego. pp. 131-142.
- Schulz, D. (1980). Evaluation of subacute toxicity with special consideration to gross pathology and histopathology in fish. **In:** Methoden der Toxizitätsprüfung an Fischen. Hermann, Gunther (ed.). Boppard & Boldt; Germany.

- Segner, H., Braunbeck, T., Perkins, F.O., and T.C. Cheng. (1990). Qualitative and quantitative assessment of the response of milkfish fry to low level copper exposure. **In:** Pathology in Marine Science: Proceedings of the Third International Colloquium on Pathology in Marine Aquaculture, Gloucester Point, Virginia. Academic Press; San Diego, CA. pp. 347-368.
- Slauson, D.O. and B.J. Cooper. (1990). Mechanisms of Disease: A Textbook of Comparative General Pathology (2nd ed). Williams & Wilkins; London. pp. 541
- Smith, C.E. and R.G. Piper. (1975). Lesions associated with chronic exposure to ammonia. **In:** The Pathology of Fishes. W.E. Ribelin and G. Migaki (eds.). University of Wisconsin Press; Madison, Wisconsin. pp. 497-514.
- SSNDC. (1997). Systematic Standardized Nomenclature for Diagnostic Criteria. Society of Toxicologic Pathology; New Jersey, USA.
- Tafanelli, R. and R.C. Summerfelt. (1975). Cadmium induced histopathological changes in goldfish. **In:** Pathology of Fishes, W.E. Ribelin and G. Migaki (eds.). University of Wisconsin Press. Madison, Wisconsin. pp. 613-645.
- Taylor, P. (1986). Practical Teratology. Academic Press; Montreal. pp. 171
- Thomson, R.G. (1988). Special Veterinary Pathology. B.C. Decker Inc; Scarborough. pp. 661
- Thomson, R.G. (1984). General Veterinary Pathology (2nd ed.). W.B. Saunders; Toronto. pp. 463
- Tones, P.I. and C.G. Rousseaux. (1992). Application of fish behaviour and pathology to toxicity identification evaluation procedures. SETAC 13th Ann. Mtg. Cincinnati, OH, November 1992.
- Trump, B.F., Jone, R.T., and S. Sahaphong. (1975). Cellular effects of mercury on fish kidney tubules. **In:** Pathology of Fishes. W.E. Ribelin and G. Migaki (eds.). University of Wisconsin Press; Madison, Wisconsin. pp. 585-612.

- Villeneuve, D.C., Chu, I.H., and C.G. Rousseaux. (1994). Toxicological studies on mixtures of chemical contaminants in the Great Lakes. **In:** Toxicology of Chemical Mixtures: From Real Life Examples to Mechanisms of Toxicological Interactions. R. Yang (ed.). Academic Press; San Diego, CA.
- Walsh, A.H. and W.E. Ribelin. (1975). The pathology of pesticide poisoning. **In:** The Pathology of Fishes. W.E. Ribelin, and G. Migaki (eds.). University of Wisconsin Press; Madison, Wisconsin. pp. 515-558.
- Wilson, J.G. and F.C. Fraser. (1977). The Handbook of Teratology, Vols. 1-4. Plenum Press; New York.
- Yamashita, M., Kinae, N., Kimura, I., Ishida, H., Kumai, H., and G. Nakamura. (1990). The Croaker (*Nibea mitsukurii*) and the Sea Catfish (*Plotosus anguillaris*): Useful biomarkers of the coastal pollution. **In:** Biomarkers of Environmental Contamination. J.F. McCarthy and L.R. Shugart (eds.). Lewis Publishers; Chelsea, Michigan. pp.73-87.
- Yasutake, W.T. (1970). Comparative histopathology of epizootic salmonid virus diseases. **In:** A Symposium on Diseases of Fishes and Shellfishes. Snieszko, S.F. (ed.). *Amer. Fish. Soc. No. 5*; Washington, D.C.

B. Journal Articles:

- Abbasi, A.R., Shackley, S.E., and P.E. King. (1995). Effects of copper on the ultrastructure of muscle cells of herring. *Pak. J. Zool.* **27(1)**: 83-87.
- Abel, P.D. and J.F. Skidmore. (1975). Toxic effects of an anionic detergent on the gills of rainbow trout. *Water Res.* **9**: 759-765.
- Adam, B. and U. Schwevers. (1993). Demonstration of sublethal damages of loaches as a result of clay industry intake. *Z. Fischko.* **2(1)**: 27-43.
- Adams, S.M. *et al.* (1996). Downstream gradients in bioindicator responses: point source contaminant effects on fish health. *Can. J. Fish Aquat. Sci.* **53**: 2177-2187.

- Adams, S.M., Shepard, K.L., Greely, M.S., Jimenez, B.D., Ryon, M.G., Shugart, L.R., McCarthy, J.F., and D.E. Hinton. (1989). The use of bioindicators for assessing the effects of pollutant stress on fish. *Mar. Environ. Res.* **28**: 459-464.
- Andrews, A.K., Van Valin, C.C., and B.E. Stebbings. (1966). Some effects of heptachlor on bluegills (*Lepomis macrochirus*). *Trans. Am. Fish Soc.* **95**: 297.
- Anees, M.A. (1976). Intestinal pathology in a freshwater teleost, *Channa punctatus* (Bloch) exposed to sublethal and chronic levels of three organophosphorus insecticides. *Acta Physiol. Latinoam.* **26**: 63-67.
- Anthony, J., Banister, E., and Oloffs, P.C. (1986). Effect of sublethal levels of Diazinon: Histopathology of liver. *Bull. Environ. Contam. Toxicol.* **37(4)**: 501-507.
- Aoki, K. (1978). Effects of cadmium on embryos and fry of the medaka, *Oryzias latipes*. *Zool. Mag.* **87**: 91-97.
- Areechon, N. and J.A. Plumb. (1990). Sublethal effects of Malathion on Channel Catfish. *Bull. Environ. Contam. Toxicol.* **44(3)**: 435-442.
- Armstrong, D.A. and R.E. Millemann. (1974). Pathology of acute poisoning with the insecticide sevin in the bent-nosed clam, *Macoma nasuta*. *J. Invertebr. Pathol.* **24**: 201-212.
- Baatrup, E. (1991). Structural and functional effects of heavy metals on the nervous system, including sense organs, of fish. *Comp Biochem. Physiol. C* **100C(1-2)**: 253-257.
- Baker, J.T. P. (1969). Histological and electron microscopical observations on copper poisoning in the winter flounder (*Pseudopleuronectes americanus*). *J. Fish Res. Board Can.* **26**: 2785-2793.
- Bakthavathsalm, R., Ravikumar, G., and U. Balasubramanian. (1987). Effects of lindane and atropine sulfate on the tissues of fish, a chronotoxicological approach. *Chemosphere* **16(6)**: 1339-1345.
- Banerjee, S. and S. Bhattacharya. (1994). Histopathology of kidney of *Channa punctatus* exposed to chronic nonlethal level of phenthoate, mercury and ammonia. *Ecotoxicol. Environ. Saf.* **29(3)**: 265-275.

- Banister, A.E. and P.C. Oloffs. (1986). Effects of sublethal levels of diazinon: Histopathology of liver. *Bull. Environ. Contam. Toxicol.* **37**: 501-507.
- Bano, Y. and M. Hasan. (1990). Histopathological lesions in the body organs of catfish (*Heteropneustes fossilis*) following mercury intoxication. *J. Environ. Sci. Health B.* **25B(1)**: 67-85.
- Basch, R.E., Nowton, M.E., Truchan, J.C., and C.M. Getterolf. (1971). Chlorinated municipal waste toxicities to rainbow trout and fathead minnows. *EPA Water Pollut. Con. Res. # 18050 GZZ 10/71*.
- Becker, D.S., Ginn, T.C., Landolt, M.L., and D.B. Powell. (1987). Hepatic lesions in English Sole from Commencement Bay, Washington. *Mar. Environ. Res.* **23(3)**: 153-173.
- Benedetti, I., Albano, A.G., and L. Mola. (1989). Histomorphological changes in some organs of the Brown Bullhead (*Ictalurus nebulosus*) following short and long term exposure to copper. *J. Fish Biol.* **34**: 272-280.
- Bengeri, K.V. and H.S. Patil. (1986). Lead induced histological changes in the liver of *Puntius arulius*. *J. Anim. Morphol. Physiol.* **33(1-2)**: 147-150.
- Bengtsson, B.E., Bengtsson, A., and U. Tjarlund. (1988a). Effects of pulp mill effluents on vertebrae of Forhorn Sculpin, bleak, and perch. *Arch. Environ. Contam. Toxicol.* **17**: 789-797.
- Bengtsson, B.E., Lansson, A., Bengtsson, A., and L. Renberg. (1988b). Sublethal effects of tetrachloro-1-2 benzoquinone, a component in bleachery effluent from pulp mills on vertebral quality and physiological parameters in *Fourhom sculpin*. *Ecotoxicol. Environ. Saf.* **15(1)**: 62-71.
- Benville, P.E. (Jr.), Smith, C.E., and W.E. Shanks. (1968). Some toxic effects of dimethyl sulfoxide in salmon and trout. *Toxicol. Appl. Pharmacol* **12**: 156-178.

- Bhatnagar, S.L. and R.S. Shrivastava. (1975). Histopathological changes due to copper in *Heteropneustes fossilis*. (abstract). *Indian Sci. Congr. Assoc. Proc.* **62**: 173.
- Black, J.J. (1983). Field and laboratory studies of environmental carcinogenesis in Niagara River fish. *J. Great Lake Res.* **9(2)**: 326-334.
- Blakley, B.R., Gagnon, J.M., and C.G. Rousseaux. (1991). The effect of 2,4,-D on chemical- and viral-induced tumor formation in mice. *Am. J. Vet. Res.* **52**: 593-595.
- Bodammer, J.E. and R.A. Murchelano. (1990). Cytological study of vacuolated cells and other aberrant hepatocytes in Winter Flounder from Boston Harbor. *Cancer Res.* **50**: 6744-6756.
- Branchaud, A., Gendron, A., Fortin, R., Anderson, P.D., and P.A. Spear. (1995). Vitamin A stores, teratogenesis, and EROD activity in white sucker, *Catostomus commersoni*, from Rivière des Prairies near Montréal and a reference site. *Can. J. Fish. Aquat. Sci.* **52**: 1703-1713.
- Brecher, R.W. (1997). Risk Assessment. *Toxicol. Pathol.* **25**: 23-26.
- Bromage, N.R. and A. Fuchs. (1976). A histological study of the response of the interrenal cells of the goldfish (*Carassium auratus*) to treatment with sodium lauryl sulphate. *J. Fish Biol* **9**: 529-535.
- Brown, E.R., Koch, E., Sinclair, R.F., Spitzer, R., and O. Callaghan. (1979). Water pollution and diseases in fish. *J. Environ. Pathol. Toxicol.* **2**: 917-925.
- Brown, V.M., Mitrovic, V.V., and G.T.C. Stark. (1968). Effects of chronic exposure to zinc on toxicity of a mixture of detergent and zinc. *Water Res.* **2**: 255-263.
- Brusle, J. (1991). The eel (*Anguilla sp.*) and organic chemical pollutants. *Sci. Total Environ.* **102**: 1-19.
- Bucher, F. and R. Hoffer. (1993). The effects of treated domestic sewage on three organs (gills, kidney and liver) of Brown Trout. *Water Res.* **27(2)**: 255-261.

- Buckley, J.A., Whitmore, C.M., and R.I. Matsuda. (1976). Changes in blood chemistry and blood cell morphology in coho salmon (*Oncorhynchus kisutch*) following exposure to sublethal levels of total residual chlorine in municipal wastewater. *J. Fish. Res. Board Can.* **33**: 776-782.
- Burdick, G.E., Harris, E.J., Dean, H.J., Walker, R.M., Skea, J., and D. Colby. (1964). The accumulation of DDT in lake trout and the effect on reproduction. *Trans. Am. Fish Soc.* **93**: 127-136.
- Burkhalter, D.E. and C.M. Kaya. (1977). Effects of prolonged exposure to ammonia on fertilized eggs and sac fry of rainbow trout (*Salmo gairdneri*). *Trans. Am. Fish Soc.* **106**: 470-475.
- Cameron, J.A. and R.L. Smith. (1980). Ultrastructural effects of crude oil on early life stages of Pacific herring. *Trans. Am Fish Soc.* **109**: 224-228.
- Carmichael, W.W. (1988). Toxins fo freshwater algae. pp. 121-147 **In**: A.T. Tu (ed.). Handbook of natural toxins, Volume 3. Marcel Dekker, New York.
- Chakrabarti, P., Kumar, D., and M. Ghosal. (1993). Cadmium induced microanatomical and histological alterations on the olfactory epithelium of *Anabas testudineus*. *J. Freshwater Biol.* **5(3)**: 253-262.
- Chevalier, G.L. and G. Moreau. (1985). Histopathological and electron microscopic studies of gills of Brook Trout from acidified lakes. *Can. J. Zoo.* **63**: 2062-2070.
- Chliamovitch, Y.P. and C. Kuhn. (1977). Behavioural, haematological and histological studies on acute toxicity of bis-(tri-n-butyltin)-oxide on *Salmo gairdneri* Richardson and *Tilapia rendalli* Boulenger. *J. Fish Biol.* **10**: 575-585.
- Chouhan, M.S. and A.K. Pandey. (1987). Histopathological changes in the gills of *Puntius ticto* following Khan River water exposure under ambient laboratory conditions. *J. Environ. Biol.* 1987. **8(2)**: 121-127.
- Christie, R.M. and H.I. Battle. (1963). Histological effects of 3-trifluoromethyl-4-nitrophenol (TFM) on larval lamprey and trout. *Can. J. Zool.* **41**: 51-61.

- Colgrove, G.S. (1966). Histological and hematological changes in accompanying sexual maturation of sockeye salmon in the Fraser River system. *Int. Pac. Salmon Fish. Comm. Bull.* **20**: 1-28.
- Colt, J. and G. Tchbanoglous. (1978). Chronic exposure of channel catfish to ammonia: Effects on growth and survival. *Aquaculture* **15**: 353-372.
- Cooper, K.R., L. McGeorge, M.A. Mayes, and M.G. Barron. (1991). *Aquat. Toxicol. and Risk Assessment*. American Society for Testing and Materials. **14**: 67-83.
- Cope, O.B. (1966). Contamination of the freshwater ecosystem by pesticides. *J. Appl. Ecol.* **3 (Suppl)**: 33-44.
- Cope, O.B., Wood, E.M., and G.J. Wallen. (1970). Some chronic effects of 2,4-D on the bluegill *Lepomis macrochirus*. *Trans. Am. Fish Soc.* **99**: 1-12
- Cope, O.B., McCraren, M.P., and L.L. Eller. (1969). Effects of dichlobenil on two fish pond environments. *Weed Sci* **17**: 158-165.
- Couch, J.A. (1991). Spongiosis hepatitis: Chemical induction, pathogenesis and possible neoplastic fate in a teleost fish model. *Toxicol. Pathol.* **19(3)**: 237-250.
- Couch, J.A., Winstead, J.T., Hammes, D.J., and L.R. Goodman. (1979). Vertebral dysplasia in young fish exposed to the herbicide Trifluralin. *J. Fish. Dis.* **2**: 35-42.
- Coulliard, C.M., Hodson, P.V., Gagnon, P., and J.J. Dodson. (1995). Lesions and parasites in White Suckers in bleached kraft pulp mill contaminated and reference to rivers. *Environ. Toxicol. Chem.* **14(6)**: 1051-1060.
- Coulliard, C.M., Berman, R.A., and J.C. Panisset. (1988). Histopathology of Rainbow Trout exposed to a bleached kraft pulp mill effluent. *Arch. Environ. Contam. Toxicol.* **17(3)**: 319-323.
- Courtney, L.A. and J.A. Couch. (1984). Usefulness of *Cyprinodon variegatus* and *Fundulus grandis* in carcinogenicity testing: advantages and special problems. *National Cancer Institute Monograph* **65**: 83-96.

- Crandall, C.A. and C.J. Goodnight. (1963). The effects of sublethal concentrations of several toxicants to the common guppy *Lebistes reticulatus*. *Trans. Am. Microsc. Soc.* **83**: 59-73.
- Crespo, S. and R. Sala. (1986). Ultrastructural alterations of the dogfish gill filament related to experimental aquatic zinc pollution. *Dis. Aquat. Org.* **1(2)**: 99-104.
- Cross, J.N. (1985). Fin erosion among fishes collected near a Southern California municipal wastewater outfall (1971-1982). *Fish. Bull.* **83**: 195-206.
- D'Agpstomo, F., Di-Marco, C., Melodia, F., and L. Vigano. (1992). Cellular and cytogenetic damage in fish exposed *in situ* to water from a polluted river. *Boll. Soc. Ital. Biol. Sper.* **68(8-9)**: 549-553.
- Daoust, P.Y., Wobeser, G., and J.D. Newstead. (1984). Acute pathological effects of inorganic mercury and copper in gills of Rainbow Trout. *Vet. Pathol.* **21**: 93-101.
- Dauba, F., Kugler, J., Belaud, A., and R. Labat. (1992). Signs of the sub-lethal ammonia toxicity to Rainbow Trout in natural streams. *Ichthyophysiol. Acta.* **15**: 99-114.
- Davis, J.C. (1976). Progress in sublethal effect studies with kraft pulp mill effluent and salmonids. *J. Fish Res. Board Can.* **33**: 2031-2033.
- Daye, P.G., and E.T. Garside. (1976). Histopathologic changes in surficial tissues of brook trout, *Salvelinus fontinalis* (Mitchell), exposed to acute and chronic levels of pH. *Can. J. Zool.* **54**: 2140-2155.
- DeCew, M. (1972). Antibiotic toxicity, efficacy and teratogenicity in adult spring chinook salmon *Oncorhynchus tshawytscha*. *J. Fish. Res. Board Can* **29**: 1513-1317.
- De-peyster, A., Donohoe, R., Slymen, D.J., Froines, J.R., Oliveieri, A.W., and D.M. Eisenberg. (1993). Aquatic biomonitoring of reclaimed water for potable use: The San Diego Health Effects Study. *J. Toxicol. Environ. Health* **39(1)**: 121-141.
- Dethlefsen, J. (1980). Observations on fish diseases in the German Blight and their possible relation to pollution. *Rapp. P. V. Re'vn. Cons. Int. Explor. Mer.* **179**: 110-117.

- Dethlefsen, V. and B. Watermann. (1980). Epidermal papillomas of North Sea Dabs, histology, epidemiology and relation to dumping from TiO₂ industry. Special Meeting on Diseases of Commercially Important Marine Fishes and Shellfishes. *Int. Counc. Explor. Sea.* **8**.
- Dey, S. and S. Bhattacharya. (1989). Ovarian damage to *Channa punctatus* after chronic exposure to low concentration of Elsan, mercury and ammonia. *Ecotoxicol. Environ. Saf.* **17(2)**: 247-257.
- Diaz-Yubero, M.A. (1980). Present situation of fish pathology in Spain. *Bull. Off. Int. Epizoot.* **92(9-10)**: 989-993.
- DiMichele, L. and M.H. Taylor. (1978). Histopathological and physiological responses of *Fundulus heteroclitus* to naphthalene exposure. *J. Fish Res. Board Can.* **35**:1060-1066.
- Dixon, D.G. and G. Leduc. (1981). Chronic cyanide poisoning of rainbow trout and its effects on growth, respiration, and liver histopathology. *Arch. Environ. Contam. Toxicol.* **10**: 117-131.
- Doudoroff, P. and M. Katz. (1953). Critical review of literature on the toxicity of industrial wastes and their components to fish. Metals as salts. *Sewage Ind. Wastes.* **25(7)**: 802-839.
- Down, N.E. and J.F. Leatherland. (1989). Histopathology of gonadal neoplasms in cyprinid fish from the lower Great Lakes of North America. *J. Fish. Dis.* **12(5)**: 415-437.
- Dubale, M.S. and P. Shah. (1981). Histopathology of the kidney of the fish *Channa punctatus* exposed to cadmium in India. *J. Anim. Morphol. Physiol.* **28(1-2)**: 166-171.
- Eisler, R.E. and G.R. Gardner. (1973). Acute toxicology to an estuarine teleost of mixtures of cadmium copper and zinc salts. *J. Fish. Biol.* **5**: 131-142.
- Eller, L.L. (1971). Histopathologic lesions in Cutthroat Trout exposed chronically to the insecticide endrin. *Amer. J. Pathol.* **64**: 321-326.
- Eller, L.L. (1969). Pathology in Redear Sunfish exposed to Hydrothol 191. *Trans. Amer. Fish. Soc.* **98**: 52-59.

- Establier, R., Gutierrez, M., and A. Arias. (1978a). Accumulation and histopathological effects of inorganic and organic mercury in the lisa *Mugil auratus* Risso. *Invest. Pesq.* **42**: 65-80.
- Establier, R., Gutierrez, M., and A. Arias. (1978b). Accumulation of inorganic mercury from seawater by the robalo, *Dicentrarchus labrax* L., and the histopathological effects. *Invest. Pesq.* **42**: 471-483.
- Eurell, J.A. and W.E. Haensly. (1982). The histology and ultrastructure of the liver of Atlantic Croaker fish from the Gulf of Mexico. *J. Fish. bioil.* **21(1)**: 113-125.
- Fischer-Schrel, T. and R.W. Hoffmann. (1988). Gill morphology of native Brown Trout experiencing acute and chronic acidification of a brook in Bavaria, FRG. *Dis. Aquat. Org.* **4(1)**: 43-51.
- Folmar, L.C., Gardner, G.R., Hickey, J., Bonomelli, S., and T. Moody. (1993). Serum chemistry and histopathological evaluations of Brown Bullheads from the Buffalo and Niagara Rivers, New York. *Arch. Environ. Contam. Toxicol.* **51(2)**: 298-303.
- Fries, C. and M.R. Tripp. (1976). Effects of phenol on clams. *Mar. Fish. Rev.* **38**: 10-11.
- Fromm, P.O. and R.H. Schiffman. (1958). Toxic action of hexavalent chromium on largemouth bass. *J. Wild. Mgmt.* **22**: 40-44.
- Fujiya, M. (1961). Effects of kraft pulp mill wastes on fish. *J. Water Pollut. Control Fed.* **33**: 968-977.
- Gardner, G.R. (1978). A review of histopathological effects of selected contaminants on some marine organisms. *Mar. Fish Rev.* **40**: 51-52.
- Gardner, G.R. and G. LaRoche. (1973). Copper induced lesions in estuarine teleosts. *J. Fish. Res. Board Can.* **30**: 363-368.
- Gardner, G.R. and R.J. Pruell. (1987). A histopathological and chemical assessment of Winter Flounder, lobster and soft shelled clam indigenous to Quincy Bay, Boston

Harbor and an *in situ* evaluation of oysters including sediment chemistry. U.S. EPA Report, Region I, Boston. MA.

Gardner, G.R. and P.P. Yevich. (1988). Comparative histopathological effects of chemically contaminated sediment on marine organisms. *Mar. Environ. Res.* **24**: 311-316.

Gardner, G.R. and P.P. Yevich. (1970). Histological and hematological responses of an estuarine teleost to cadmium. *J. Fish. Res. Board Can.* **27**: 2185-2196.

Gardner, G.R. and P.P. Yevich. (1969). Studies on the blood morphology of three estuarine cyprinodontiform fishes. *J. Fish. Res. Board Can.* **26**: 433-447.

Gardner, G.R., Pruell, R.J., and L.C. Folmar. (1989). A comparison of both neoplastic and non neoplastic disorders in Winter Flounder from eight areas in New England. *Mar. Environ. Res.* **28**: 393-397.

Gas, N. (1973). Cytophysiologie du foie de carpe (*Cyprinus carpio*, L.). II. Modalités d'altération des ultrastructures au cours d'un jeûne expérimental prolongé. *Journal de Physiologie (Paris)* **66**: 282-303.

Ghosh, A.R. and P. Chakrabarti. (1993). Histopathological and histochemical changes in liver, pancreas and kidney of the freshwater fish *Heteropneustes fossilis* exposed to cadmium. *Environ. Ecol.* **11(1)**: 185-188.

Gilderhaus, P.A. (1966). Some effects of sublethal concentrations of sodium arsenite on bluegills and the aquatic environment. *Trans. Am. Fish. Soc.* **95**: 289-296.

Gill, T.S., Pant, J.C., and H. Tewari. (1989). Cadmium nephropathy in *Puntius conchonus*. *Ecotoxicol. Environ. Saf.* **18(2)**: 165-172.

Gill, T.S. and J. Pant. (1987). Hematological and pathological effects of chromium toxicosis in the freshwater fish *Barbus conchonus*. *Water Air Soil Pollut.* **35(3-4)**: 241-250.

Gingerich, W.H., Weber, L.J., and R.E. Larson. (1978). Carbon tetrachloride-induced retention of sulfobromophthalein in the plasma of rainbow trout. *Toxicol. Appl. Pharmacol.* **43**: 147-158.

- Grant, B.F. and P.M. Mehrle. (1970). Chronic endrin poisoning in goldfish, *Carassius auratus*. *J. Fish. Res. Board Can.* **27**: 2225-2232.
- Grizzle, J.M., Horowitz, S.A., and D.R. Strength. (1988). Caged fish as monitors of pollution: Effects of chlorinated effluent from a wastewater treatment plant. *Water Resour. Bull.* **24(5)**: 951-959.
- Gronlund, W.D., Stein, J.E., Chan, SinLam, Brown, D.W., McCain, B.B., Landahol, J.T., Clark, R.C., Krahn, M.M., Myers, M.S., and U. Varanasi. (1991). Multidisciplinary assessment of pollution at three sites in Long Island Sound. *Estuaries.* **14(3)**: 299-305.
- Guo, Yongcan, Zhou, Qingshan, Xie, Jinyun, Ou, Deyou, Lai, Qin, Chen, Ruisheng, Liu, Yanxin, and Xueshuang He. (1991). Toxicity of heavy metals in river sediments to aquatic organisms: Toxicity of various forms of lead to fishes. *Acta. Hydrobiol.* **15(3)**: 234-241.
- Gupta, A.K. and V.K. Rajbanshi. (1988). Acute toxicity of cadmium to *Channa punctatus*. *Acta. Hydrochim. Hydrobiol.* **16(5)**: 525-535.
- Gutierrez, M. Establier, R., and A. Arias. (1978). Accumulation and histopathological effects of cadmium and mercury on the Sapo *Halobatrachus didactylus*. *Invest Pesq.* **42**: 141-154.
- Haensly, W.E., Neff, J.M., Sharp, J.R., Morris, A.C., Bedgood, M.F., and P.D. Boem. (1982). Histopathology of *Pleuronectes platessa* from Aber Wrach and Aber Benoint, Brittany, France: Long term effects of the Amoco Cadiz oil spill. *J. Fish. Dis.* **5**: 57-60.
- Haley, R.K., Hall, T.J., and T.M. Bousquet. (1995). Effects of biologically treated bleached kraft mill effluent before and after mill conversion to increased chlorine dioxide substitution: Physiological, pathohistological and biochemical studies. *Environ. Toxicol. Chem.* **14(2)**: 297-298.
- Hall, T.J., Haley, R.K., Borton, D.L., Walsh, A.H., and R.E. Wolke. (1992). Histopathology of Rainbow Trout after long term exposure to biologically treated bleached kraft mill effluent in experimental stream channels. *Can. J. Fish. Aquat. Sci.* **49(5)**: 939-944.

- Hampton, J.A., P.A. McCuskey, R.S. McCuskey, and D.E. Hinton. (1985). Functional units in rainbow trout (*Salmo gairdneri*, Richardson) liver: I. Arrangement and histochemical properties of hepatocytes. *Anatomical Record* **213**: 166-175.
- Harada, M. (1995). Minamata disease: Methylmercury poisoning in Japan caused by environmental pollution. *Crit. Rev. Toxicol.* **25(1)**: 1-24.
- Hard, G.C., Williams, R., and J. Lee. (1979). Histopathology of superficial fish tumours found during a cancer study of demsal fish in Port Philip Bay, Victoria, Australia. *J. Fish. Des.* **2**: 455-467.
- Harshbarger, J.C. and J.B. Clark. (1990). Epizootiology of neoplasms in bony fishes of North America. *Sci. Total Environ.* **94**: 1-32.
- Hawkes, J.W. (1980). The effects of xenobiotics on fish tissues: Morphological studies. *Fed. Proc.* **39**: 3230-3236.
- Hawkes, J.W., Gruger, E.H. (Jr.), and O.P. Olson. (1980). Effects of petroleum hydrocarbons and chlorinated biphenyls on the morphology of the intestine of chinook salmon (*Oncorhynchus tshawytscha*). *Environ Res.* **23**: 149-161.
- Hawkins, W.E., Walker, W.W., Overstreet, R.M., Lytle, J.S., and T.F. Lytle. (1990). Carcinogenic effects of some polycyclic aromatic hydrocarbons on the Japanese Medaka and guppies in waterborne exposures. *Sci. Total Environ.* **94(1-2)**: 155-167.
- Hawkins, W.E., Walker, W.W., Overstreet, R.M., Lytle, T.F., and J.S. Lytle. (1988). Dose related carcinogenic effects of water borne benzo[a]pyrene on livers of two small fish species. *Ecotoxicol. Environ. Saf.* **16(3)**: 219-231.
- Hawkins, W.E., Tate, L.G., and T.G. Sarphie. (1980). Acute effects of cadmium on the spot, *Leiostomus xanthurus* (Teleostei): Tissue distribution and renal ultrastructure. *J. Toxicol. Environ. Health* **6**: 283-295.
- Hayes, M.A., Smith, I.R., Rushmore, T.H., Crane, T.L., Thorn, C., Kocal, T.E., and H.W. Ferguson. (1990). Pathogenesis of skin and liver neoplasms in white suckers from industrially polluted areas in Lake Ontario. *Sci. Total Environ.* **94(1-2)**: 105-123.

- Hildebrandt, P.K. (1991). Regulatory aspects and potential pitfalls of toxicologic pathology. **In:** Handbook of Toxicologic Pathology. W.M. Haschek and C.G. Rousseaux (eds.). Academic Press; San Diego, CA. pp.143-153.
- Hilden, M. and D. Rapport. (1993). four centuries of cumulative impacts on a Finnish river and its estuary: An ecosystem health approach. *J. Aquat. Ecosyst. Health* **2(4)**: 261-275.
- Hinton, D.E., Lantz, R.C., Hampton, J.A., McCuskey, P.R., McCuskey, R.S., and J.B. Pritchard. (1987). Normal versus abnormal structure: Considerations in morphologic responses of Teleosts to pollutants. *Environ. Health Perspect.* **71**: 139-146.
- Hinton, D.E., Klaunig, J.E., Lipsky, M.M. (1978). PCB-induced alterations in teleost liver: A model for environmental disease in fish. *Mar. Fish Rev.* **40**: 47-50.
- Hodson, P.B., McWhirter, M.M., Ralph, K., Gray, B., Thivierge, D., Carey, J., VanderKraak, G.J., Whittle, D.M., and M.C. Levesque. (1992). Effects of bleached kraft mill effluent on fish in the St. Maurice River, Quebec. *Environ. Toxicol. Chem.* **11**: 1635-1651.
- Hoffer, R. and F. Bucher. (1990). Fish pathological aspects of paper and pulp production in Austria. *Oesterr. Fisch.* **47(8)**: 1616-1622.
- Hughes, G.M., Perry, S.F. and V.M. Brown. (1979). A morphometric study of effects of nickel, chromium and cadmium on the secondary lamellae of rainbow trout gills. *Water Res.* **13**: 665-679.
- Janicki, R.H. and W.B. Kinter. (1971). DDT: Disrupted osmoregulatory events in the intestine of the eel. *Science* **173**: 1146-1148.
- Jauch, D. (1979). Gill lesions in cichlid fishes after intoxication with the insecticide fenthion. *Experientia* **35**: 371-372.
- Johnson, L.L, Stein, J.E., Collier, T.K., Casillas, E., and B.B. McCain. (1992). Bioindicators of contaminant exposure, liver pathology and reproductive development in prespawning female Winter Flounder from urban and non urban estuaries on the Northeast Atlantic Coast. *NOAA Tech. Memo.* **82**.

- Johnson, L.L., Casillas, E., Collier, T.K., McCain, B.B., and U. Varnasi. (1988). Contaminant effects on ovarian development in English Sole from Puget Sound Washington D.C. *Can J. Fish. Aquat. Sci.* **45**: 2133-2146.
- Julliard, A.K., Saucier, D., and L. Astic. (1993). Effects of chronic low level copper exposure on ultrastructure of the olfactory system in Rainbow Trout. *Histol. Histopathol.* **8(4)**: 655-672.
- Karlsson Norrgren, Rnn, P., Haux, C., and L. Foerlin. (1985). Cadmium induced changes in gill morphology of zebrafish and Rainbow Trout. *J. Fish. Biol.* **27(1)**: 81-95.
- Kendall, M.W. (1977). Acute effects of methylmercury toxicity in channel *catfish* (*Ictalurus punctatus*) liver. *Bull. Environ. Contam. Toxicol.* **18**: 143-151.
- Kent, M.L., Myers, M.S., Hinton, D.E., Eaton, W.D., and R.A. Elston. (1988). Suspected toxicopathic hepatic necrosis and megalocytosis in pen reared Atlantic Salmon in Puget Sound, Washington D.C. *Dis. Aquat. Org.* **49**: 91-100.
- Khan, R.A., Barker, D., Hooper, R., and E.M. Lee. (1992). Effect of pulp and paper effluent on a marine fish *Pseudopleuronectes americanus*. *Bull. Environ. Contam. Toxicol.* **48(3)**: 449-456.
- Khan, R.A. and J. Thulin. (1991). Influence of pollution on parasites of aquatic animals. *Adv. Parasitol.* **30**: 201-238.
- Khargarot, B.S. (1992). Copper induced hepatic ultrastructural alterations in the snake headed fish *Channa punctatus*. *Ecotoxicol. Environ. Safety.* **23(3)**: 282-293.
- Khargarot, B.S. and R.C. Somani. (1980). Toxic effects of mercury on the gills of a freshwater teleost, *Punctius sophore* Hamilton. *Curr. Sci.* **49**: 832-834.
- Khargarot, B.S. and D.M. Tripathi. (1992). Sterioscan observations of the skin of catfish following chromium exposure. *J. Environ. Sci. Health A*. **27A(4)**: 1141-1148.
- Kierstead, J.T., Chapman, P., Bishay, F., Power, E., Hall, K., Harding, L., McLeary, D., Nassichuk, M., and W. Knapp. (1990). Refinery effluent biomonitoring. **In:** Proceedings of the Seventeenth Annual Aquatic Toxicology Workshop, Vancouver, B.C. *Can. Tech. Rep. Fish. Aquat. Sci.* **1774**: 196-206.

- Kimura, I. and M. Ando. (1986). Fish neoplasms and environmental chemicals. *J. Hyg. Chem.* **32(5)**: 317-334.
- Kinae, N., Yamashita, M., Tomita, I., Kumura, I., Ishida, H., Kumai, H., and G. Nakamura. (1990). A possible correlation between environmental chemicals and pigment cell neoplasia in fish. *Sci. Total Environ.* **94**: 143-153.
- King, S.F. (1962). Some effects of DDT on the guppy and the brown trout. *U.S. Fish Wildl. Serv. Spec. Sci. Rep. Fish* **399**: 1-22.
- Klaunig, J.E., Lipsky, M.M, Trump, B.F., and D.E. Hinton. (1979). Biochemical and ultrastructural changes in teleost liver following subacute exposure to PCB. *J. Environ. Pathol. Toxicol.* **2**: 953-963.
- Kloepper, P.J., Swanson, S.M., Merchant, T., Schuyer, R., and J.W. Owens. (1994). Exposure of fish to biologically treated bleached kraft effluent: Biochemical, physiological and pathological assessment of Rocky Mountain Whitefish and Longnose Sucker. *Environ. Toxicol. Chem.* **13(9)**: 1469-1482.
- Koehler, A. (1991). Lysosomal perturbations in fish liver as indicators for toxic effects of environmental pollution. *Comp. Biochem. Physiol. C* **100C(1-2)**: 123-127.
- Koehler, A. (1989). Cellular effects of environmental contamination in fishes from the River Elbe and the North Sea. *Environ. Res.* **28(1-4)**: 417-424.
- Koenst, W.M., Smith, L.L. (Jr.) and S.J. Brodirius. (1977). Effect of chronic exposure of brook trout to sublethal concentrations of hydrogen cyanide. *Environ. Sci. Technol.* **11**: 883-887.
- Kosaric, Z., Srebocan, E., and R. Novak. (1993). Histopathological changes in the gills of some marine teleosts. *Veterinarski Archiv.* **63(4)**: 209-215.
- Kotak, B.G. Kenefick, S.L., Fritz, D.L., Rousseaux, C.G., Prepas, E.E., and S.E. Hrudey. (1992). Occurrence and toxicological evaluation of cyanobacterial toxins in Alberta surface waters. *Water.Res.* **27**: 495-506.

- Kyle, M.E. and J.L. Farber. (1991). Biochemical mechanisms of toxic cell injury. **In:** Handbook of Toxicologic Pathology. W.M. Haschek and C.G. Rousseaux (eds.). Academic Press; San Diego, CA. pp. 71-91.
- Lakota, S., Raszka, A., Kupczak, I, Hlond, S., Stefan, J., and J. Roszkowski. (1978). The effect of methoxychlor and propoxur on the health of carp fry *Cyprinus carpio* L. *Acta Hydrobiol.* **20:** 197-205.
- Langer, M. and V. Storch. (1978). *Zur Ultrastruktur der Hepatocyten von Teleosteren bei Nahrungsentzug. Zeitschrift für mikroskopisch-anatomische Forschung (Leipzig)* **92:** 641-654.
- Lanno, R.P., Hicks, B., and J.W. Hilton (1987). Histological observations on intrahepatocytic copper-containing granules in rainbow trout reared on diets containing elevated levels of copper. *Aqua. Toxicol.* **10:** 251-263.
- Lauren, D.J., Mayes, M.A., and M.G. Barron. (1991). The fish gill: A sensitive target for waterborne pollutants. *Aquatic Toxicology and Risk Assessment*. American Society for Testing and Materials. **14:** 67-83.
- Laurent, P. and S.F. Perry. (1991). Environmental effects on fish gill morphology. *Physiol. Zool.* **64:** 4-25.
- Leatherland, J.F. (1982). Effects of a commercial trout diet on the liver of fed and fasted yearling coho salmon, *Oncorhynchus kisutch* Walbaum. *J. Fish Biol.* **21:** 311-319.
- Lehtinen, K.J., Notini, M., and L. Lander. (1984). Tissue damage and parasite frequency in flounders chronically exposed to bleached kraft pulp mill effluents. *Ann. Zoo. Fenn.* **21:** 23-28.
- Lehtinen, K.J. and A.A. Oikari. (1980). Sublethal effects of kraft pulp mill waste water on the perch studied by rotary flow and histological techniques. *Ann. Zoo. Fenn.* **17:** 255-259.
- Leino, R.L., Wilkinson, P., and J.G. Anderson. (1987). Histopathological changes in the gills of Pearl Dace and Fathead Minnow from experimentally acidified Canadian lakes. *Can. J. Fish. Aquat. Sci.* **44(S1):** 126S -134S.

- Leland, H.V. (1983). Ultrastructural changes in hepatocytes of juvenile Rainbow Trout and mature Brown Trout exposed to copper and zinc. *Environ. Toxicol. Chem.* **2**: 343-368.
- Lesniak, J.A. and S.M. Ruby. (1982). Histological and quantitative effects of sublethal cyanide exposure on oocyte development in Rainbow Trout. *Arch. Environ. Contam. Toxicol.* **13**: 101-104.
- Lind, D.T., Smith, L.L. (Jr), and S.J. Brodirus. (1977). Chronic effects of hydrogen cyanide on the fathead minnow. *J. Water Pollut. Control Fed.* **49**: 262-268.
- Lindesjö, E. and J. Thulin. (1992). Skeletal deformity of Northern Pike related to pulp mill effluents. *Can. J. Fish. Aquat. Sci.* **49**: 166-172.
- Lindesjö, E. and J. Thulin. (1990). Fin erosion of perch and ruffe in pulp mill effluent. *Dis. Aquat. Org.* **8**: 119-126.
- Lindesjö, E. and J. Thulin. (1987). Fin erosion of perch in pulp mill effluent. *Bull. Eur. Assoc. Fish. Pathol.* **7**: 11-14.
- Lindesjö, E., Thulin, J., Bengtsson, B.E., and U. Tjaamlund. (1994). Abnormalities of a gill cover bone, the operculum in perch from pulp mill effluent. *Aquat. Toxicol.* **28(3-4)**: 81-93.
- Lloyd, R. (1960). The toxicity of zinc sulfate to rainbow trout. *Ann. Appl. Biol.* **48**: 84-94.
- Lock, R.A.C. and A.P. Van Overbeeke. (1981). Effects of mercuric chloride and methylmercuric chloride on osmoregulatory function of the gills in rainbow trout. *Comp. Biochem. Physiol. C. Comp. Pharmacol.* **68**: 151-159.
- Longwell, A.C. and J.B. Hughes. (1980). Cytologic, cytogenetic and developmental state of Atlantic Mackerel eggs from sea surface water of the New York Bight and prospects for biological effects monitoring with ichthyoplankton. *Rapp. P. V. Re'vn. Comp. Int. Explor. Mer.* **179**: 275-291.
- Lowe, J.I., Parrish, P.R., Patrick, J.M. (Jr), and J. Forester. (1972). Effects of the polychlorinated biphenyl Aroclor 1254 on the American oyster *Crassostrea virginica*. *Mar. Biol.* **17**: 209-214.

- Lowe, J.I., Wilson, P.D., Ricke, A.J., and A.J. Wilson Jr. (1971). Chronic exposure of oysters to DDT, toxaphene, and parathion. *Proc natl Shellfish Assoc* **61**: 71-79.
- Lowe, J.I. (1965). Some effects of endrin on estuarine fishes. *Proc. Annu. Conf. Southeast Assoc. Game Fish Comm* **19**: 271.
- Malins, D.C., McCain, B.B., Landahl, J.T., Myers, M.S., Krahn, M.M., Brown, D.W., Chan, S.L., and W.T. Roubal. (1988). Neoplastic and other diseases in fish in relation to toxic chemicals. *Aquat. Toxicol.* **11**: 43-67.
- Mallatt, J. (1985). Fish gill structural changes induced by toxicants and other irritants: A statistical review. *Can. J. Fish. Aquat. Sci.* **42(4)**: 630-648.
- Mathur, D.S. (1975). Histopathological changes in the liver of fishes resulting from exposure to dieldrin and lindane. *Toxicon.* **13**: 109-110.
- Mathur, D.S. (1962). Studies on the histopathological changes induced by DDT in liver, kidney and intestine of certain fishes. *Experientia* **18**: 506-509.
- Matthiessen, P. and A.E. Bradfield. (1973). The effects of dissolved zinc on the gills of the stickleback. *J. Fish Biol.* **5**: 607-613.
- Matton, P. and Q.N. LaHam. (1969). Effect of the organophosphate dylox on rainbow larvae. *J. Fish Res. Board Can.* **26**: 2193
- Mayer, F.L., Mehrle, P.M., and P.L. Crutcher. (1978). Interactions of toxaphene and vitamin C in channel catfish. *Trans. Am. Fish Soc.* **107**: 326-333.
- McBride, J.R., Donaldson, E.M., and G. Derksen. (1979). Toxicity of landfill leachates to underyearling rainbow trout *Salmo gairdneri*. *Bull. Environ. Contam. Toxicol.* **23**: 806-813.
- McBride, J., Strasdine, G., and U.H.M. Fagerlund. (1975). Acute toxicity of kanamycin to steelhead trout *Salmo gairdneri*. *J. Fish Res. Board Can.* **32**: 5554-5558.

- McCain, B.B., Hodgins, H.O., Gronlund, W.D., Hawkes, J.W., Brown, D.W., Myers, M.S., and J.H. Vandermeulen. (1978). Bioavailability of crude oil from experimentally oiled sediments to English sole (*Parophrys vetulus*) and pathological consequences. *J. Fish Res. Board Can.* **35**: 657-664.
- McCain, B.B., Pierce, K.V., Wellings, S.R., and B.S. Miller. (1977). Hepatomas in marine fish from an urban estuary. *Bull Environ. Contam. Toxicol.* **18**: 1-2.
- McCraren, J.P., Cope, O.B., and L.L. Eller. (1969). Some chronic effects of diuron on bluegills. *Weed Sci.* **17**: 497-504.
- Minchew, C.D. and T.D. Yarbrough. (1977). The occurrence of fin rot in Mullet associated with oil contamination of an estuarine pond ecosystem. *J. Fish. Biol.* **10**: 319-323.
- Mitchell, S.J. and J.J. Cech. (1983). Ammonia caused gill damage in channel catfish. *Can. J. Fish. Aquat. Sci.* **40**: 242-247.
- Mitrovic, V.V., Brown, V.M., Shurben, D.G., and M.H. Berryman. (1968). Some pathological effects of sub-acute and acute poisoning of Rainbow Trout by phenol in hard water. *Water Res.* **28**: 249-254.
- Mitz, S.V. and J.P. Giesy. (1985). Sewage effluent biomonitoring: Survival, growth and histopathological effects in channel catfish. *Ecotoxicol. Environ. Safety* **10(1)**: 22-39.
- Mount, D.I. (1968). Chronic toxicity of copper to the fathead minnow. *Water Res.* **2**: 215-223.
- Mount, D.I. and G.J. Putnicki. (1966). Summary report of the 1963 Mississippi River fishkill. *North Am. Wildl. Natur. Resour. Conf. Trans.* **31**.
- Mount, D.I. (1962). Chronic effects of endrin on bluntnose minnows and guppies. *U.S. Fish Wildl. Serv. Res. Rep.* **58**.
- Mukhopadhyay, M.K. and S.K. Konar. (1988). Skeletal abnormalities in the fish *Tilapia mossambica* exposed to zinc and iron. *Environ. Ecol.* **6(2)**: 519-520.

- Murchelano, R.A. and R.E. Wolke. (1991). Neoplasms and non-neoplastic liver lesions in Winter Flounder from Boston Harbor, Massachusetts. *Environ. Health Perspect.* **90**: 17-26.
- Murugesan, A.G. (1988). Toxicity of textile mill effluent to an air breathing fish. *PhD Thesis*; Madurai Kamraj University; Madurai, India.
- Murugesan, A.G., Muthu, SP., and M.A. Haniffa. (1989). Cytopathological changes in erythrocytes of the catfish *Heteropneustes* exposed to textile mill effluent. *Curr. Sci.* **58(5)**: 268-270.
- Murugesan, A.G. and M.A. Haiffa. (1992). Histopathological and histochemical changes in the oocytes of the air breathing fish *Heteropneustes fossilis* exposed to textile mill effluent. *Bull. Environ. Contam. Toxicol.* **48(6)**: 929-936.
- Myers, M.S., Olson, O.P., Johnson, L.L., Stehr, C.S., Hom, T., and U. Varanasi. (1992). Hepatic lesions other than neoplasms in subadult flatfish from Puget Sound, Washington D.C.: Relationships with indices of contaminant exposure. *Mar. Environ. Res.* **34(1-2)**: 45-51.
- Myers, M.S., Landahol, J.T., Krahn, M.M., Johnson, L.L., and B.B. McCain. (1990). Overview of studies on liver carcinogenesis in English Sole from Puget Sound: Evidence for a xenobiotic chemical etiology, pathology and epizootiology. *Sci. Total Environ.* **94**: 33-50.
- Myers, M.S., Rhodes, L.D., and B.B. McCain. (1987). Pathologic anatomy and patterns of occurrence of hepatic neoplasms, putative pre-neoplastic lesions and other idiopathic hepatic conditions in English Sole from Puget Sound, Washington, D.C. *J. Natl. Cancer Inst.* **78(2)**: 333-363.
- Narain, A.S. (1990). Liver and kidney damage in *Heteropneustes fossilis* and *Anabas testudineus* exposed to sewage. *Acta. Hydrochim. Hydrobiol.* **18(2)**: 255-261.
- Nath, K. and N. Kumar. (1990). Gonadal histopathology following nickel intoxication in the giant gourami, a freshwater tropical perch. *Bull. Environ. Contam. Toxicol.* **45**: 299-304.

- Nath, K. and N. Kumar. (1989). Nickel induced histopathological alterations in the gill architecture of a tropical freshwater perch (*Colisa fasciatus*). *Sci. Total Environ.* **80(2-3)**: 293-296.
- Neilson, A.H., Allard, A.S., Fischer, S., Malmberg, M., and T. Viktor. (1990). Incorporation of a sub acute test with zebrafish into a hierarchical system for evaluating the effect of toxicants in the aquatic environment. *Ecotoxicol. Environ. Saf.* **20(1)**: 82-97.
- Nestel, H. and J. Budd. (1975). Chronic oral exposure of rainbow trout *Salmo gairdneri* to a polychlorinated biphenyl (Arochlor 1254). Pathological effects. *Can. J. Comp. Med.* **39**: 208-215.
- Newman, M.W. and S.A. MacLean. (1974). Physiological response of the cunner, *Tautoglabrus adspersus*, to cadmium. VI. Histopathology. NOAA Tech. Rep. NMFS Spec. Sci. Rep. Fish **681**: 27-33.
- Onwumere, B.G. and A.A. Oladimeji. (1990). Accumulation of metals and histopathology in *Oreochromis niloticus* exposed to treated NNPC Kaduna, Nigeria petroleum refinery effluent. *Ecotoxicol. Environ. Safety* **19(2)**: 123-134.
- Ooi, V. and F.K. Law. (1989). Changes induced by cadmium in the kidney of Black Sea Bream (*Mylio macrocephalus*). *Bull. Environ. Contam. Toxicol.* **43(5)**: 769-775.
- Oronsaye, J.A.O. (1989). Histological changes in the kidneys and gills of the stickleback *Gasterosteus aculeatus* exposed to dissolved cadmium in hard water. *Ecotoxicol. Environ. Saf.* **13(2)**: 279-290.
- Overstreet, R.M. (1988). Aquatic pollution problems, Southeastern U.S. coasts: histopathological indicators. *Aqua. Toxicol.* **11**: 213-239.
- Owens, J.W. (1991). Hazard assessment of pulp and paper effluents in the aquatic environment. *Environ. Toxicol Chem.* **10**: 1511-1540.
- Ozoh, P.T.E. (1979a). Malformations and inhibitory tendencies induced to *Brachydanio rerio* (Hamilton-Buchanan) eggs and larvae due to exposures in low concentrations of lead and copper ions. *Bull. Environ. Contam. Toxicol.* **21**: 668-675.

- Ozoh, P.T.E. (1979b). Studies on intraperitoneal toxicity of lead to *Cichlasoma nigrofasciatum* (Guenther) development. *Bull Environ Contam Toxicol* **21**: 676-682.
- Pande, R.K. and S.K. Pande. (1988). Tolerance measurement and histopathological observations on the gills of *Mystus vittatus* under the toxic stress of the fertilizer NPK. *Acta. Hydrochim. Hydrobiol.* **16(5)**: 551-556.
- Parsons, P.A. (1990). Fluctuating asymmetry: An epigenetic measure of stress. *Biol. Rev. Camb. Philos. Soc.* **65(2)**: 131-145.
- Payne, J.F., Kiceniuk, J.W., Squires, W.R., and G.L. Fletcher. (1978). Pathological changes in a marine fish after a 6-month exposure to petroleum. *J. Fish Res. Board Can* **35**: 665-667.
- Pearce, J.B. and L. Despres-Patanjo. (1988). A review of monitoring strategies and assessments of estuarine pollution. *Aqua. Toxicol.* **11**: 323-343.
- Pereira, J.J. (1988). Morphological effects of mercury exposure on Windowpane Flounder gills as observed by scanning electron microscopy. *J. Fish. Biol.* **33(4)**: 571-580.
- Phillpart, J.C., Gillet, A., and J.C. Micha. (1988). Fish and their environment in large European river ecosystems. *Sci Eau* **7(1)**: 115-154.
- Pierce, K.V., McCain, B.B., and S.R. Willings. (1978). Pathology of hepatomas and other liver abnormalities in English Sole from the Duwarnish River Estuary, Seattle, Washington. *J. Natl. Cancer Inst.* **50**: 1445-1449.
- Poirier, A., Baudion-Laurencin, B., Bodenner, G., and C. Quentel. (1986). Experimental poisoning of the Rainbow trout by engine diesel oil: Mortalities, haematological changes and histology. *Aquaculture* **55(2)**: 115-137.
- Poleksic, V. and V. Karan. (1995). Pathohistological effects of some herbicides to carp. *Pesticidi.* **10(1)**: 41-47.
- Pundir, R. and A.B. Saxena. (1990). Seasonal changes in the testes *Puntius ticto*, and their relation to heavy metal toxicity. *Bull. Environ. Contam. Toxicol.* **45(2)**: 288-293.

- Racicot J.G., Gaudet, M., and C. Leray. (1975). Blood and liver enzymes in rainbow trout *Salmo gairdneri* Rich. with emphasis on their diagnostic use: Study of CCl₄ toxicity and a case of *Aeromonas* infection. *J. Fish Biol.* **7**:825-835.
- Rajbanshi, V.K. and A.K. Gupta. (1988). Alterations in the architecture of the gill surface produced by water borne copper in *Heteropneustes fossilis*. *Acta Hydrochim. Hydrobiol.* **16(3)**: 325-331.
- Ram, R.N. and A.G. Sathyanesan. (1987). Histopathological changes in liver and thyroid of *Channa punctatus* in response to ammonium sulfate fertilizer treatment. *Ecotoxicol. Environ. Saf.* **13(2)**: 195-190.
- Ram, R.N. and A.G. Sathyanesan. (1986). Effect of a mercurial fungicide on the gonadal development of *Channa punctatus*. *Ecotoxicol. Environ. Saf.* **11(3)**: 352-360.
- Ram, R.N. and S.K. Singh. (1988). Carbofuran induced histopathological and biochemical changes in liver of the Teleost fish *Channa punctatus*. *Ecotoxicol. Environ. Saf.* **16(3)**: 194-201.
- Ramalingam, K. (1988). Effects of DDT, Malathion and Mercury on the liver histomorphology of the fish *Sarotherodon mossambicus*. *Environ. Ecol.* **6(3)**: 761-762.
- Rastogi, A. and S.K. Kulshrestha. (1990). Effect of sublethal doses of three pesticides on the ovary of a carp minnow *Rasbora daniconius*. *Bull. Environ. Contam. Toxicol.* **45(5)**: 742-747.
- Reichenbach-Klinke, H.-H. (1965). Der Phenolgehalt des Wassers in seiner Auswirkung auf den Fishorganismus. *Arch. Fischereiwiss.* **16**: 176.
- Reimschuessel, R., Bennett, R.O, and M.M. Lipsky. (1992). A classification system for histological lesions. *J. Aquat. Anim. Health.* **4(2)**: 135-143.
- Reimschuessel, R., Bennett, R.O, May, E.B., and M.M. Lipsky. (1989). Renal histopathological changes in the Goldfish after sublethal exposure to hexachlorobutadiene. *Aquat. Toxicol.* **15(2)**: 169-180.

- Riji, J.K. and N. Jayabalan. (1993). Sublethal effects of Endosulfan on the histology and protein pattern of *Cyprinus carpio* gills. *J. Appl. Ichthyol.* **9(1)**: 49-56.
- Robinette, H.R. (1976). Effect of selected sublethal levels of ammonia on the growth of channel catfish. *Progr. Fish. Cult.* **38**: 26-29.
- Roskam, R.T. (1965). A case of copper pollution along the Dutch shore. *Int. Counc. Explor. Sea. C.M.* **40**.
- Rousseaux, C.G. (1997). Symposium Introduction: Risk Assessment and the Toxicologic Pathologist. *Toxicologic Pathology.* **15**: 22.
- Rousseaux, C.G. (1985). Automated differential staining for cartilage and bone in whole mount preparations of vertebrates. *Stain Technol.* **60(5)**: 295-297.
- Rousseaux, C.G., Branchaud, A., and P.A. Spear. (1995). Evaluation of liver histopathology in St. Lawrence lake sturgeon (*Acipenser fulvescens*) in comparison with a reference population. *Environ. Toxicol. Chem.* **14(5)**: 843-849.
- Rousseaux, C.G., Thompson, B.E., and B. Zintel. (1992). The effect of water source on the growth and development of CD-1 mouse limb buds in submerged culture. *Toxicol. Methods.* **2**: 177-187.
- Rousseaux, C.G., Schiefer, H.B., Hancock, D.S., and E.D. Olfert. (1990). Differentiation of lesions caused by mycotoxin T-2 from autolytic morphologic change in CD-1 mice. *J. Comp. Pathol.* **103**: 379-385.
- Ruby, S.M., Dixon, D.G., and G. Leduc. (1979). Inhibition of spermatogenesis in rainbow trout during chronic cyanide poisoning. *Arch. Environ. Contam. Toxicol.* **8**: 533-544.
- Saltes, J.G. and G.C. Bailey. (1984). Use of fish gill and liver tissue to monitor zinc pollution. *Bull. Environ. Contam. Toxicol.* **32(2)**: 233-237.
- Sangalang, G.B. and M.J. O'Halloran. (1972). Cadmium-induced testicular injury and alterations of androgen synthesis in brook trout. *Nature* **240**: 470-471.
- Sastry, K.V. and P.K. Gupta. (1978a). Effect of mercuric chloride on the digestive system of *Channa punctatus*. A histopathological study. *Environ. Res.* **16**: 270-278.

- Sastry, K.V. and P.K. Gupta. (1978b). Histopathological and enzymological studies on the effects of chronic lead nitrate intoxication in the digestive system of a freshwater teleost, *Channa punctatus*. *Environ. Res.* **17**: 472-479.
- Sastry, K.V. and S.K. Sharma. (1978). The effect of endrin on the histopathological changes in the liver of *Channa punctatus*. *Bull. Environ. Contam. Toxicol.* **20**: 674-677.
- Saucier, D., Astic, L, Rioux, P., and F. Godinot. (1991). Histopathological changes in the olfactory organ of Rainbow Trout induced by early chronic exposure to a sublethal copper concentration. *Can. J. Zool.* **69(8)**: 2239-2245.
- Schoor, W.P. and J.A. Couch. (1979). Correlation of mixed function oxidase activity with ultrastructural changes in the liver of marine fish. *Cancer. Biochem. Biophys.* **4**: 95-103.
- Schulz, D. (1971). Light microscopic, biochemical and electron microscopic changes on the exocrine pancreas of the carp caused by the herbicide *Dowpon*. *Z Angew. Zool.* **58**: 63-97.
- Schulz, D. (1970). Research into the side effects of the herbicide NaTA₂ (sodium trichloroacetate) on the carp. *Zentralbl. Veterinaermed Reihe A* **17**: 230-251.
- Schwaiger, J., Bucher, F., Ferling, H., Kalbfus, W., and R.D. Negele. (1992). A prolonged toxicity study on the effects of sublethal concentrations of bis(tri-n-butyltin)oxide: Histopathological and histochemical findings in Rainbow Trout. *Aquat. Toxicol.* **23(1)**: 31-48.
- Secombes, C.J., Fletcher, T.C., O'Flynn, J.A., Costello, M.J., Stagg, R., and D.F. Houlihan. (1991). Immunocompetence as a measure of the biological effects of sewage sludge pollution in fish. *Comp. Biochem. Physiol C.* **100C(1-2)**: 133-136.
- Segner, H. and H. Moeller. (1984). Electron microscopical investigations on starvation-induced liver pathology in flounders *Plactichthys flesus*. *Mar. Ecol. Progr. Ser.* **19**: 193-196.

- Sehgal, R. and A.B. Saxena. (1986). Toxicity of zinc to viviparous fish, *Libistes reticulatus*. *Bull. Environ. Contam. Toxicol.* **36(6)**: 888-894.
- Servos, M.R., Carey, J.H., Ferguson, M.L., VanderKraak, G., Ferguson, H., Parrott, J., Gorman, K., Cowling, R., Carey, J.H., and E.R. Hall. (1992). Impact of a modernized bleached kraft mill on white sucker population in the Spanish River, Ontario. *Water Pollut. Res. J. Can.* **27(3)**: 423-437.
- Sharples, A.D., Campin, D.N., and C.W. Evans. (1994). Fin erosion in a feral population of goldfish exposed to bleached kraft mill effluent. *J. Fish. Dis.* **17(5)**: 483-493.
- Shukla, J.P. and K. Pandey. (1984). Impaired spermatogenesis in arsenic treated freshwater fish, *Colisa fasciatus* (Bl. and Sch.). *Toxicol. Lett.* **21**: 191-195.
- Simpson, M.G. (1992). Histopathological changes in the liver of Dab from a contamination gradient in the North Sea. *Mar. Environ. Res.* **34(1-2)**: 39-43.
- Simpson, M.G., Allen, S.L., and R. Sheldon. (1989). Histopathological assessment of neurotoxic injury in mammals: Possible applications for similar studies on fish. *Environ. Res.* **28(1-4)**: 437-440.
- Sindermann, C.J. (1979). Pollution induced diseases and abnormalities of fish and shellfish: A review. *Fish. Bull.* **76**: 717-749.
- Sivarajah, K., Franklin, C.S., and W.P. Williams. (1978). Some histopathological effects of Arochlor 1254 on the liver and gonads of rainbow trout, *Salmo gairdneri*, and carp, *Cyprinus carpio*. *J. Fish Biol.* **13**: 411-414.
- Skidmore, J.F. and P.W.A. Tovell. (1972). Toxic effects of zinc sulfate on the gills of rainbow trout. *Water Res.* **6**: 217-230.
- Skinner, R.H. (1982). The interrelation of water quality, gill parasites, and gill pathology of some fishes from South Biscayne Bay, Florida. *Fish. Bull. U.S. Nati. Mar. Fish Serv.* **80(2)**: 269-280.
- Sloof, W. (1982). Skeletal anomalies in fish from polluted surface waters. *Aquatic Toxicol.* **2**: 217-230.

- Smart, G. (1976). The effect of ammonia exposure on gill structure of the rainbow trout, *Salmo gairdneri*. *J. Fish Biol.* **8**: 741-745.
- Smith, I.R. Ferguson, H.W., and M.A. Hayes. (1989). Histopathology and prevalence of epidermal papillomas epidemic in Brown Bullhead and White Sucker populations from Ontario, Canada. *J. Fish. Dis.* **12**: 373-388.
- Smith, C.E., Peck, T.H., Klauda, R.J., and J.B. McClaren. (1979). Hepatomas in Atlantic tomcod *Microgadus tomcod* (Walbaum) collected in the Hudson River estuary in New York. *J. Fish Dis.* **2**: 313-319.
- Smith, C.E. and R.G. Piper. (1972). Pathological effects in formalin-treated rainbow trout (*Salmo gairdneri*). *J. Fish Res. Board Can.* **29**: 328-329.
- Sneed, R.A., Grimes, S.D., Schultze, A.E., Brown, A.P., and P.E. Ganey. (1997). Bacterial endotoxin enhances the hepatotoxicity of allyl alcohol. *Toxicology and Applied Pharmacology.* **144**: 77-87.
- Solangi, M.A. and R.M. Overstreet. (1982). Histopathological changes in two estuarine fishes exposed to crude oil and its water soluble fractions. *J. Fish. Dis.* **5**: 13-35.
- Sorensen, E.M.B. (1988). Selenium accumulation, reproductive status and histopathological changes in environmentally exposed redear sunfish. *Arch. Toxicol.* **61(4)**: 324-329.
- Sorensen, E.M.B., Harlan, C.W., and J.S. Bell. (1983a). Histopathological changes in selenium exposed fish. *Am. J. Forensic Med. Pathol.* **4**: 111-123.
- Sorensen, E.M.B., Harlan, C.W., and J.S. Bell. (1983b). Hepatocytes changes following selenium accumulation in a freshwater teleost. *Am. J. Forensic Med. Pathol.* **4**: 25-32.
- Sorensen, E.M.B., Harlan, C.W., and J.S. Bell. (1982). Renal changes in selenium exposed fish. *Am. J. Forensic Med. Pathol.* **3**: 123-129.
- Sorensen, E.M.B. (1976). Ultrastructural changes in the hepatocytes of green sunfish, *Lepomis cyanellus* Rafinesque, exposed to solutions of sodium arsenate. *J. Fish Biol.* **8**: 29-240.

- Southgate, P. (1979). Laboratory diagnosis of fish disease. *In-Pract.* **16(5)**: 252-255.
- Srivastava, A.K. (1987). Changed induced by lead in fish testes. *J. Environ. Biol.* **8(4)**: 329-332.
- Stehr, C.M. and M.S. Myers. (1990). The ultrastructure and histology of cholangiocellular carcinomas in English Sole from Puget Sound, Washington, D.C. *Toxicol. Pathol.* **18(3)**: 362-372.
- Stehr, C.M., Rhodes, L.D., and M.S. Myers. (1988). The ultrastructure and histology of hepatocellular carcinomas of English Sole from Puget Sound, Washington D.C. *Toxicol. Pathol.* **16**: 418-431.
- Stock, J.N. and O.B. Cope. (1969). Some effects of TEPA, an insect chemosterilant, on the guppy, *Poecilia reticulata*. *Trans. Am. Fish Soc.* **98**: 280-287.
- Stott, G.G., Haensly, W.E., Neff, J.M., and J.R. Sharp. (1983). Histopathologic survey of ovaries of Plaice from AberWrac'h and Aber Benoit, Brittany France - Long term effects of the Amoco Cadiz Crude Oil Spill. *J. Fish. Dis.* **6**: 429-437.
- Stott, G.G., McArthur, N.H., Tarpley, R., Jacobs, V., and R.F. Sis. (1981). Histopathologic survey of ovaries of fish from petroleum production and control sites in the Gulf of Mexico. *J. Fish. Biol.* **18**: 261-269.
- Sukumar, A. and P.R. Karpagaganapathy. (1992). Pesticide-induced atresia in ovary of a fresh water fish *Colisa lalia*. *Bull. Environ. Contam. Toxicol.* **48(3)**: 457-462.
- Takashi, H. (1982). *An Atlas of Fish Histology: Normal and Pathological Features*. Stuttgart Publication; New York, New York.
- Teh, S.J., Adams, S.M., and D.E. Hinton. (1997). Histopathologic biomarkers in feral freshwater fish populations exposed to different types of contaminant stress. *Aquatic Toxicology* **37**: 51-70.

- Temminck, J.H.M., Bouwmeister, P.J., DeJong, P., and J.H.J. VandenBerg. (1983). An ultrastructural study of chromate induced hyperplasia in the gill of Rainbow Trout. *Aquat. Toxicol.* **4(2)**: 165-179.
- Thiyagarajah, A., Zwerner, D.E., and W.J. Hargis. (1989). Renal lesions in estuarine fishes collected from the Elizabeth River, Virginia. *J. Environ. Pathol. Toxicol. Oncol.* **9(3)**: 261-268.
- Thulin, J., Hoglund, J., and E. Lindesjö. (1988). Diseases and parasites of fish in bleached kraft mill effluent. *Water Sci. Technol.* **20**: 179-180.
- Thurston, R.V., Russo, R.C., Meyn, E., Zajdel, R.K., and C.E. Smith. (1986). Chronic toxicity of ammonia to Fathead Minnow. *Trans. Am. Fish. Soc.* **115(2)**: 196-207.
- Tuurala, H. and A. Soivio. (1982). Structural and circulatory changes in the secondary lamellae of *Salmo gairdneri* gills after sublethal exposures to dehydroabietic acid and zinc. *Aquat. Toxicol.* **2**: 21-29.
- Van Bohemen, C.G., Lambert, J.G.D., and J. Peute. (1981). Annual changes in plasma and liver relation to vitellogenesis in the female rainbow trout *Salmo gairdneri*. *General and Comparative Endocrinology.* **44**: 94-107.
- VandeKamp, G. (1977). Vertebral deformities of herring around the British Isles and their usefulness for a pollution monitoring programme. International Council of Exploration of the Sea Publication. CM-E:5.
- Van Valin, C.C., Andrews, A.K., and L.L. Eller. (1968). Some effects of mirex on two warm-water fishes. *Trans. Am. Fish Soc.* **97**: 185-196.
- VanLeeuwen, C.J., Helder, T., and W. Seinen. (1986). Aquatic toxicological aspects of dithiocarbamates and related compounds, teratogenicity and histopathology. *Aquat. Toxicol.* **9**: 147-159.
- Vethaak, A.D., Bucke, D., Lang, T., Wester, P.W., Jol, J., and M. Carr. (1992). Fish disease monitoring along a pollution transect: A case study using Dab in the German Bight. *Mar. Ecol. Prog. Ser.* **91(1-3)**: 173-192.

- Vethaak, D. and J. Meer. (1991). Fish disease monitoring in the Dutch part of the North Sea in relation to the dumping of waste from titanium dioxide production. *Chem. Ecol.* **5(3)**: 149-170.
- Vethaak, D. (1989). Fish disease monitoring in the Dutch part of the North Sea in relation to the dumping of wastes from titanium dioxide production. *Eighty International Ocean Disposal Symposium Abstracts*.
- Voyer, R.A., Yevich, P.P., and C.A. Barszcz. (1975). Histological and toxicological responses of the mummichog, *Fundulus heteroclitus* (L.), to combinations of levels of cadmium and dissolved oxygen in freshwater. *Water Res.* **9**: 1069-1074.
- Waite, D.T, Joshi, S.R., Sommerstad, H., Wobeser, G., and A.A. Gajadhar. (1990). A toxicological examination of whitefish and Northern Pike exposed to uranium mine tailings. *Arch. Environ. Contam. Toxicol.* **19(4)**: 578-582.
- Wajsbrodt, N., Gasith, A., Diamant, A., and D.M. Popper. (1993). Chronic toxicity of ammonia to juvenile Gilthead Seabream *Sparus aurata* and related histopathological effects. *J. Fish. Biol.* **42(3)**: 321-328.
- Waluga, D. (1966a). Phenol effects on the anatomicohistopathological changes in bream (*Abramis brama* L.). *Acta Hydrobiol* **8**: 55-78.
- Waluga, D. (1966b). Phenol induced changes in the peripheral blood of the breams, *Abramis brama* (L.) *Acta Hydrobiol.* **8**: 87-95.
- Wasserman, J. and S.J. Koeppe. (1977). An ultrastructural study of mercury-induced injury in the intact proximal tubule of the common mummichog *Fundulus heteroclitus*. *NJ Acad. Sci. Bull* **22**: 47.
- Watermann, B. and H. Kranz. (1992). Pollution and fish diseases in the North Sea: Some historical aspects. *Mar. Pollut. Bull.* **24(3)**: 131-138.
- Wedemeyer, G.A., Nelson, N.C., and W.T. Yasutake. (1979). Physiological and biochemical aspects of ozone toxicity to rainbow trout *Salmo gairdneri*. *J. Fish Res. Board Can* **36**: 605-614.

- Wedemeyer, G.A. and W.T. Yasutake. (1978). Prevention and treatment of nitrite toxicity in juvenile steel-head trout (*Salmo gairdneri*). *J. Fish Res Board Can* **35**: 822-827.
- Wedemeyer, G.A. and W.T. Yasutake. (1974). Stress of formalin treatment in juvenile spring chinook salmon (*Oncorhynchus tshawytscha*) and steelhead trout *Salmo gairdneri*. *J. Fish Res. Board Can* **31**: 179-184.
- Weis, J.S. and P. Weis. (1989). Effects of environmental pollutants on early fish development. *Aquat. Sci.* **1**: 45-73.
- Weis, P. and J.S. Weis. (1976). Abnormal locomotion associated with skeletal malformations in the sheephead minnow exposed to Malathion. *Environ. Res.* **12**: 196-200.
- Wester, P.W. (1991). Histopathological effects of environmental pollutants β -HCH and methyl mercury on reproductive organs in freshwater fish. *Comp. Biochem. Physiol. C.* **100C(1-2)**: 237-239.
- Wester, P.W. and J.H. Canton. (1992). Histopathological effects in *Poecilia reticulata* exposed to methyl mercury chloride. *Toxicol. Pathol.* **20(1)**: 81-92.
- Wester, P.W. and J.H. Canton. (1991). The usefulness of histopathology in aquatic toxicity studies. *Comp. Biochem. Physiol. C.* **100C(1-2)**: 115-117.
- Wester, P.W. and J.H. Canton. (1986). Histopathological study of *Oryzias latipex* (medaka) after long-term β -hexachlorocyclohexane exposure. *Aquat. Tox. (Amsterdam)* **9**: 1-45.
- Wester, P.W. and J.G. Vos. (1986). Toxicological pathology in laboratory fish: An evaluation with two species and various environmental contaminants. *Ecotoxicol.* **3(1)**: 21-51.
- Wilson, R.W. and E.W. Taylor. (1993). The physiological responses of freshwater Rainbow Trout during acutely lethal copper exposure. *J. Comp. Physiol. B* **163B(1)**: 38-47.
- Wise, S.A. and B.J. Koster. (1995). Considerations in the design of an environmental specimen bank: Experiences of the National Biomonitoring Specimen Bank Program. *Environ. Health Perspect.* **103(Supplement 3)**: 61S-67S.
-

- Wise, S.A., Koster, B.J., Langland, J.K., and R. Zeisler. (1993). Current activities within the National Biomonitoring Specimen Bank. *Sci. Total Environ.* **139-140**: 1-12
- Wobeser, G. (1975a). Acute toxicity of methyl mercury chloride and mercuric chloride for rainbow trout (*Salmo gairdneri*) fry and fingerlings. *J. Fish Res. Board Can.* **32**: 2005-2013.
- Wobeser, G. (1975b). Prolonged oral administration of methyl mercury chloride to rainbow trout *Salmo gairdneri* fingerlings. *J. Fish Res. Board Can* **32**: 2015-2023.
- Wolf, K., Herman, R.L, and C.P. Carlson. (1972). Fish viruses: Histopathologic changes associated with experimental Channel Catfish virus disease. *J. Fish. Res. Board Can.* **29**: 149-150.
- Wood, E.M., Yasutake, W.T., and H.E. Johnson. (1957). Acute sulfmethazine toxicity in young salmon. *Prog. Fish Cult* **19**: 64-67.
- Yasutake, W.T. (1987). Collection and preparation of fish specimens for histological examination. **Document 5**, U.S. Dept. of the Interior, Fish and Wildlife Service.
- Yasutake, W.T., Parisot, T.J., and G.W. Klontz. (1965). Virus diseases of the Salmoniae in Western United States - Aspects of pathogenesis. *Ann. N. Y. Acad. Sci.* **126**: 520-530.
- Zaki, M.I. and S.A. Saad. (1987). Pathological changes in different species and embryological stages on fish induced by urea fertilizer wastewater. *Bull. Inst. Oceanogr. Fish. Cairo.* **13(1)**: 43-57.

X. GLOSSARY

A. *Pathological Terms Used*

adenoma: benign epithelial tumor in which cells form fairly well-differentiated glandular structures.

adenomatous: resembling an adenoma, sometimes referring to glandular hyperplasia.

anemia: reduction in the oxygen transport capabilities per unit volume of blood due to below-numbers of erythrocytes and/or a decreased hemoglobin concentration. Anemias are usually secondary diseases and are classified by cause and on the basis of morphological characteristics of erythrocytes.

aneurysm: widening or dilation.

anisochromasia: variability in staining characteristics of individual cell cytoplasm and/or nuclei within a population of cells; unequal cytoplasmic staining within a single cell as seen in erythrocytes from certain anemias due to unequal distribution of hemoglobin.

anisocytosis: extreme differences in cell size within a normally uniform population, particularly seen in certain blood diseases.

anophthalmia: congenital defect where one or both eyes are absent.

atretic: atrophied to the point of almost disappearance.

atrophy: shrinkage of the volume and sometimes numbers of cells (wasting of cells, organs, or entire body resulting from various causes including necrosis and reabsorption of cells, decreased cellular proliferation, malnutrition, decreased use, pressure, ischemia, or hormonal changes).

ballooning degeneration: separation of epithelial cells from one another classically seen in the deeper cell layers of the epidermis. Usually follows intracytoplasmic edema and vacuolation.

Bowman's capsule: the filtration part of the kidney surrounding the glomerulus.

catarrhal enteritis: inflammation of any or all of the intestinal tract characterized by excessive mucus production accompanied by epithelial necrosis and desquamation. Necrosis may often predominate, in which case little or no mucus is evident from lack of a secreting membrane.

centrilobular: refers to the central area of hepatic parenchyma immediately surrounding the central vein of a liver lobule.

ceroid: high molecular weight intracellular lipofuscin pigment resulting from autoxidation of phospholipids and unsaturated fats accompanied by polymerization. Thus, ceroid is insoluble in organic solvents, characteristically acid-fast, variably PAS-positive, sudanophilic in both frozen and paraffin sections, and negative with iron stains. Ceroid is found in cases of vitamin E deficiency, wasting diseases, and old age.

cirrhosis: pathology of the liver defined by cell death (necrosis), cell regeneration and fibrosis (proliferative form of chronic hepatic inflammation characterized by replacement of parenchyma by new fibrous connective tissue generally beginning at the portal triads).

chloride cells: cells in the gills that assist in osmoregulation.

chromatin: gene carrying nuclear material of the cell; found in the nucleus.

cloudy swelling (acute cellular swelling): earliest degenerative change within a cell, caused by influx of water, characterized by enlarged cell and homogeneous “ground glass” appearance of cytoplasm.

congestion: excessive amount of blood within vessels producing a “pavementing” effect in the lumina. Cause is usually insufficient venous drainage of blood (passive).

degenerative changes: early abnormal pre-necrotic changes in cellular detail, many of which are reversible to a certain point (i.e., fatty change, hydropic degeneration, cloudy swelling, etc.).

desquamation: sloughing of cells from an epithelial surface due to necrosis, some degenerative change, or from postmortem autolysis.

dysplasia: abnormal alteration in size, shape and organization of adult cells or tissue.

edema: excess extracellular fluid resulting in a jelly appearance, or histological spaces (excessive amounts of water collecting in intercellular spaces and/or body cavities).

electron microscopy (EM): Use of a high-voltage electron beam with shorter wavelengths than visible light to observe fine structural detail not resolved with conventional light microscopy. Two-dimensional (transmission EM) and three-dimensional (scanning EM) viewing are routinely used.

enzymes: proteins capable of facilitating a chemical reaction.

enzymological: pertaining to enzymes.

epithelial: (see epithelium)

epithelium: cellular tissue at the surface of the skin; does not contain dermal structures such as scales.

epithelioma: benign neoplasm involving epithelial cells of the epidermis, including those of the adnexa.

erythema: redness of the skin caused by inflammation.

exocrine: secretory/ hormonal function of a gland.

exophthalmos (“popeye”): unilateral or bi-lateral extrusion of the eyes from their sockets commonly caused by accumulation of gas bubbles (nitrogen “gas bubble” disease) or edema fluids (osmoregulatory problems due to kidney lesions, etc.) beneath the eye globes.

extravasation: passing outside the vasculature, usually referring to blood or lymph. A large hemorrhage within a tissue.

fatty change: intracytoplasmic accumulation of neutral fat droplets. It is considered to be a degenerative change independent of, but often occurring with, necrosis and is commonly found in the liver and kidney epithelium. Fatty change results from inhibition of transport or metabolism of lipid. Because neutral fat is dissolved by organic solvents used in histological preparation, it appears as well demarcated unstained areas within the cell cytoplasm.

fibrinoid degeneration: degeneration occurring in fibrous connective tissue, probably resulting from a local antigen-antibody reaction. It appears to be either fibrin from an

inflammatory exudate or degenerative collagen, which stains dirty pink and has fewer nuclei than surrounding normal tissues.

fibroplasia or fibrosis: adequate or excessive production of new fibrous connective tissue as a repair response to cell death following or concomitant with inflammation.

granuloma: mass or focus of granulation tissue. There are two basic types: fibrous granuloma which is composed of inflammatory cells, actively proliferating fibrous connective tissue, and numerous capillary buds, and reticuloendothelial granuloma, which contains proliferating macrophages or histiocytes, usually circumscribed by a collar of lymphocytes. A granuloma is a chronic host defense mechanism to wall off site of infectious, toxic, or mechanical irritation.

Heinze bodies: round, oval to serrated, cytoplasmic inclusion bodies observed within erythrocytes, usually indicative of hemolytic anemia following exposure to certain toxic compounds. Inclusions are refractile when unstained, blue when stained with new methylene blue. They are usually located adjacent to, or protruding from, the cell wall but can be found free in the blood plasma.

hemorrhage: presence of blood outside the vasculature due to injury of the vessel walls.

hemostasis: stoppage of blood flow either by hemorrhage or in part of the vascular circulation.

histochemistry: qualitative identification of the normal and abnormal intracytoplasmic distribution of various cell products and assimilated chemicals (lipids, polysaccharides, nucleic acids, enzymes, etc.) and reaction sites by use of several methods including specific chemical stains, immunofluorescence, autoradiography, and electron microscopy.

histology: study of normal microscopic and ultrastructural anatomy of animals or plants including the structure and function of cells, tissues, and organs. This is done by observing stained paraffin tissue sections with light microscopy and ultrathin sections with electron microscopy.

Howell-Jolly bodies: round nuclear remnants eccentrically located in a young erythrocyte, usually one per cell. Can be indicative of a remissive anemia, but occur normally at low levels in the cat and the horse.

hyalin degeneration: cellular change characterized by glassy homogeneous eosinophilic material seen as droplets within cell cytoplasm or found replacing entire cells or cellular areas.

hydropic degeneration: accumulation of water within the cytoplasm of a swollen epithelial cell, appearing as a clear vacuole or vacuoles with an indistinct edge often adjacent to or surrounding the nucleus. This change may be a further sequence of cloudy swelling.

hyperchromic: more intensely staining.

hyperemia: excessive blood within the vasculature, distinguished from congestion by its “active” cause-dilated arteries delivering too much blood for proper venous drainage.

hyperplasia: increased proliferation of a cell population, usually in response to an irritant (toxic or infectious), endocrine imbalance, or nutritional deficiency. Normal tissue function and architecture may be impaired as observed in gill epithelium when hyperplasia causes overgrowth of cells (“clubbing”) and cellular fusion of filaments and lamellae.

hypertrophy: increase in individual cell size and functional ability, sometimes resulting in a concomitant increase in tissue or organ size. Hypertrophy can occur from an increase in functional demand, which may be compensatory or hormonal in origin.

infarct: localized area of tissue necrosis (usually coagulative) caused by insufficient blood supply due to vascular obstruction.

inflammation: condition characterized by heat, redness and pain; histopathologically it is visualized as exudation of inflammatory cells, necrosis (cell death) or degeneration, and edema (dynamic process of events involving vascular and exudative stages occurring only in viable tissues that have been injured by an irritant. This response permits humoral and cellular elements of the immune system to interact with the causative agent at local sites of tissue damage in order that healing may occur. Inflammation is classified according to the morphological nature of the exudate, which varies with the type of tissue involved and the causative agent. Six forms of inflammation are recognized.

serous inflammation, characterized by a watery exudation of blood serum, often in peritoneal cavities or formed vesicles, with microscopic appearance of homogeneous pink staining precipitate mixed with a few leukocytes and slight amounts of fibrin.

fibrinous inflammation, with an exudate composed predominantly of clotted fibrin, usually occurring on mucous and serous membranes, particularly the pericardium.

Microscopically, the exudate contains dirty pink staining fibrillar material adhering to a hyperemic parent surface usually accompanied by variable amounts of leukocytes, erythrocytes, and other precipitated serum proteins. A thick fibrin exudate that becomes firmly attached to its parent surface denotes a diphtheritic inflammation.

purulent inflammation, in which the exudate contains pus, which consists of variable numbers of necrotic and living neutrophils in or on the tissues accompanied by congestion and small amounts of fibrin, serum, and other leukocytes. If neutrophils predominate over other elements, the inflammation is said to be “suppurative.” Although fish have neutrophils, purulent inflammation, particularly abscesses (circumscribed accumulation of pus), rarely occurs in teleosts.

hemorrhagic inflammation, consisting of an exudate that may contain many of the other exudative components above but also large accumulations of erythrocytes obviously outside vascular channels. This exudate can occur diffusely within tissues but more often involves mucous membranes.

catarrhal or mucous inflammation, which involves only mucous membranes since the principal component of the exudate is mucous secreted from the host cells. Under the microscope, affected membranes may demonstrate hyperplasia of mucous goblet cells accompanied by attached overlying gray- or blue-staining strands of mucin. More often the membrane surface undergoes necrosis and desquamation, exposing an underlying hyperemic connective tissue infiltrated with varying amounts of lymphocytes.

lymphocytic inflammation, which results from infiltration of lymphocytes within affected tissues accompanied by some hyperemia. Histologically, tissues appear normal except for slight vascular congestion and collections of lymphocytes, often surrounding the vessels (perivascular cuffing). Tissues in which this type of inflammation commonly occurs include nervous tissue, portal triads of the liver, and lamina propria of the gut. The latter two areas normally have resident populations of lymphocytes, which vary in number according to animal species.

ischemia: insufficient blood supply.

glycogen: animal starch, usually found in the liver.

glycoprotein: a molecule containing both protein and sugar components.

glomerulus: the capillary tuft used in filtration in the kidney.

hemorrhagic: extravasation of blood; blood escapes the blood vessels.

hematocrit: the blood cell count giving measurements for white blood cells, red blood cells, hemoglobin concentration, and other hematological parameters.

hepatocytes: liver parenchymal cells.

histopathological: the microscopic evaluation of diseased tissues.

hyperplasia: an increase in the number of cells.

hypersecretion: an increase in the secretions above a normal level (can be at the organ or cellular level).

hypertrophy: increase in the size of cells.

karyolysis: necrotic change characterized by dissolution of a cell nucleus, recognized by incomplete stages where only nuclear outlines are visible.

karyorrhexis: necrotic change characterized by rupture of the nuclear membrane and fragmentation of the cell nucleus. These fragments may remain at the original site of the nucleus or may be scattered about with other necrotic debris.

lesion: a morphological abnormality that may or may not be caused by a disease (abnormal change within a cell, tissue, or organ).

leukopenia: abnormal reduction in circulating white blood cells per unit volume of blood

lumen: the hollow space in a tube.

lymph: the straw color fluid that returns to the circulation from the extracellular spaces in the tissues.

lymphoid: pertaining to the lymph system and lymph nodes.

metaplasia: change from one cell type to another within the limits of the original primary tissue, such as squamous cell metaplasia of cuboidal or columnar epithelium.

Metaplasia has been seen only in epithelium and connective tissue. The cause is a change in demand of function.

microphthalmia: congenital defect in which one or both eyeballs are abnormally small.

morphology: structure.

mucin: mucopolysaccharide cellular secretion that stains gray to blue with hematoxylin and eosin.

mucus: fluid secreted by the mucus membrane (viscid complex cellular secretion that functions as a cleansing agent, lubricant, and/or protective barrier at various membrane surfaces. Mucus is comprised of mucin, epithelial cells, leukocytes, and various inorganic salts dissolved in water, and may contain immunoglobulins and lysozymes, which provide localized protection against infectious agents.

myositis: inflammation of smooth or skeletal muscle.

myxomatous degeneration (muroid degeneration; serous atrophy of fat): proliferation of and replacement by a primitive embryonal-type connective tissue where fibrous and/or adipose connective tissues occur. Myxomatous tissue is composed of a mucinous grayish to blue loosely arranged fibrillar ground substance containing fibroblastic cells with stellate to spherical hyperchromatic nuclei. The primary cause is poor nutrition, although certain toxemias may play a role.

necrosis: irreversible changes in the nucleus and cytoplasm of the cell at some time after the cell's death. (cell or tissue death within a living body. Necrosis is classified as several histological types, including:)

coagulative necrosis, death of cells in which nuclei become pyknotic, cytoplasm becomes acidophilic, and cellular outlines and other tissue structures are still visible.

caseous necrosis, loss of differential staining with disintegration of tissue structures and cell membranes into a homogeneous mixture of granular debris that is basophilic to purple with hematoxylin and eosin.

liquefactive necrosis, rapid and complete dissolution of cells and tissue structures leaving ragged-edges spaces filled with fluid, which may or may not have a residue of pink proteinaceous material when stained. An abscess produces a

form of liquefactive necrosis in which fluid contains neutrophils, fibrin, and cellular debris.

fat necrosis, saponification of neutral fat into solvent-stable soap appearing solid and opaque within the dead fat cells. The soap may have small clefts from dissolved fatty acid crystals and should stain pink, purple, or blue, depending on which metallic ions (potassium, calcium, sodium, respectively) combined with the fatty acid radical during soap formation.

Zenker's necrosis, which is similar to coagulative necrosis but occurs only in skeletal muscle, where changes are characterized by swelling of individual muscle fibers, marked homogeneous texture and acidophilia of the sarcoplasm, obscurity of myofibrils (striations), and pyknosis of nuclei.

Further descriptions of necrosis may be based on distribution or location of the lesion-diffuse, focal, perivascular, and so on.

necrotic: (see necrosis)

neoplasia: pathological transformation of a normal host cell resulting in uncontrolled proliferation into new cells without normal histological architecture or normal cellular functions. These cells usually bear some resemblance to the normal tissue of origin, although some malignant forms may appear so undifferentiated that cell identification of the growth or tumor is difficult.

nephritis: inflammation of the kidney.

nephrosis: degenerative changes that may lead to necrosis in the nephrons of the kidney which do not involve an inflammatory process (called nephritis). Blood-borne toxic materials are common causes of nephrosis, particularly in renal tubular epithelium.

nephron: the functional and structural unit of kidney.

neutrophilia: abnormally high percentage of neutrophil granulocytes in circulating blood, which may also cause an absolute increase in total number of peripheral white blood cells (leukocytosis).

nuclear: part of the cell containing the DNA.

oocyte: the cellular egg.

osteoblast: the cell responsible for the formation of osteoid or bone matrix. An osteoblast is eventually surrounded by bone and then becomes an osteocyte.

pathology: study of the biochemical and molecular mechanisms responsible for the morphological appearance of injured cells and tissues (the medical science concerned with the study of abnormal changes, and their causes, within the cells, tissues, and organs of an individual or a population).

periportal: referring to the area of tissue immediately surrounding a portal triad within the liver.

petechiae: small pinpoint hemorrhages.

phagocytic cells: (see phagocytosis)

phagocytosis: a cellular process whereby material is taken into a cell, usually for destruction.

poikilocytosis: distortion or abnormal variation in cell shape, usually referring to erythrocytes in certain blood diseases.

polycythemia (erythrocytosis): abnormal increase in the number of red blood cells per unit volume of blood.

portal area: the region of the liver surrounding the bile duct, hepatic artery and the hepatic vein.

primary lamellae: the “trunk of the gill system”.

proliferative glomerulonephritis: inflammation of the kidney glomeruli characterized by hypertrophy of glomerular tufts due to increased infiltration of leukocytes and proliferation of endothelial and visceral epithelial cells (podocytes). The increased cellularity causes compression of glomerular capillaries, leading to thrombosis and necrosis with subsequent hemorrhage into Bowman’s space. Proliferating podocytes may cause adhesions with the parietal epithelium of Bowman’s capsule, producing “epithelial crescents.” There is no thickening of the glomerular basement membrane or alteration in foot processes of podocytes; these 2 anomalies help distinguish this condition from membranous glomerulonephritis.

proximal tubules (collecting tubules): the first part of the nephron following filtration at Bowman's space.

pyloric caeca: part of the upper gastrointestinal tract.

pyknosis: necrotic change in cell nuclei characterized by a rounding up and condensation that causes hyperchromatic staining.

secondary lamellae: the fronds or leaves of the gill system.

scoliosis: lateral curvature of the spinal column. A combination of backward curvature with the lateral curvature is termed lordoscoliosis.

telangiectasia: a defect (often congenital) where blood pools in large spaces (marked dilation of terminal blood vessels within a part, usually capillaries).

thrombocytopenia: abnormal reduction in thrombocyte or platelet cell numbers per unit volume of blood.

thrombus: blood clot, formed within a vessel or heart chamber of a living animal, which may obstruct blood flow or only partly so by attaching to the vessel wall.

vacuolation: the formation of fatty droplets in the cell.

vasodilation: enlargement of a vessel lumen.

vitellogenesis: maturation of oocytes.

XI. APPENDIX

**TECHNICAL EVALUATION OF
HISTOPATHOLOGY**

prepared by

GOLDER ASSOCIATES